

## 1

{username}

A 60-year-old male with alcohol-related cirrhosis. The severity of the liver failure was calculated by CHILD TURCOTTE PUGH, and a result of 12 points (grade C) was obtained. The patient is scheduled for elective surgery to correct an umbilical hernia.

What is the risk of perioperative morbidity for this patient?

1. 3%
2. 10%
3. 20%
4. 60%

## 2

{username}

What is the most common reason for a patient being on the kidney transplant waiting list?

1. MPGN – membranoproliferative glomerulonephritis
2. IGA NEPHROPATHY
3. DIABETES MELLITUS
4. FSGS-Focal segmental glomerulonephritis

**3**

{username}

Which of the following blood test results is most indicative of primary hyperparathyroidism?

1. Low calcium, high PTH
2. High calcium, normal PTH
3. High calcium, low PTH
4. Low calcium, low PTH

**4**

{username}

Which of the following conditions is most likely caused by a false diverticulum?

1. Diverticulitis of the sigmoid colon
2. Appendicitis
3. Meckel's diverticulum
4. Traction mid-esophageal diverticulum

**5**

{username}

Which of the following situations is the most common cause of colonic obstruction?

1. Diverticulitis
2. Foreign body
3. Feces
4. Malignant tumor

## 6

{username}

A 77-year-old male with Hodgkin's lymphoma in remission is scheduled for lymph node excision to investigate a suspected recurrence.

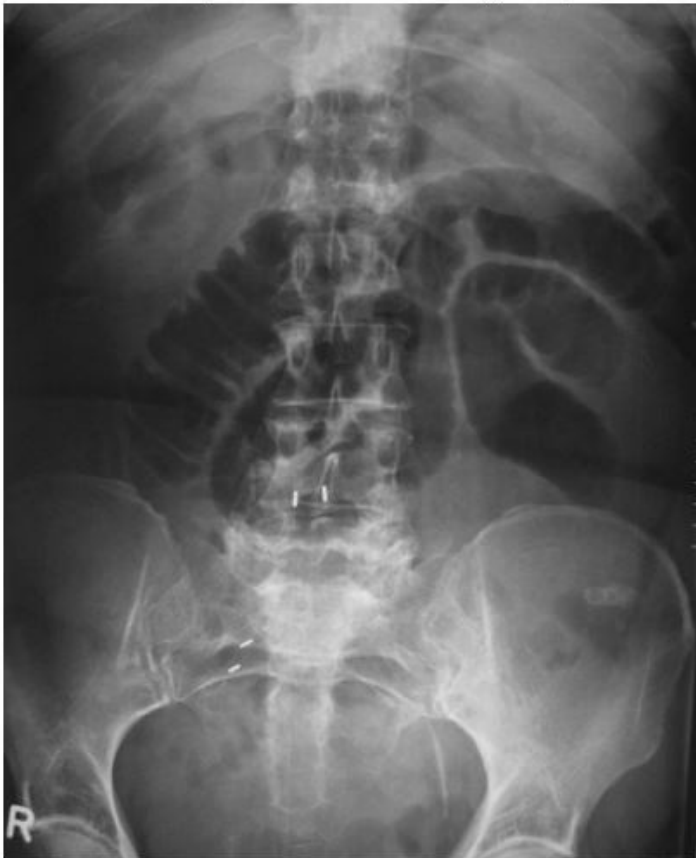Which of the following factors is considered an inhibitor of surgical wound healing?

1. Vitamin D deficiency
2. Adriamycin (doxorubicin) treatment
3. Hydroxyurea treatment
4. Hypercholesterolemia

**7**

{username}

A 55-year-old male underwent partial small intestine resection 10 years ago. At the ER, he presents with two days of persistent vomiting. An X-ray was performed (attached).



What would you expect to find in the blood tests results?

1. Hypermagnesemia
2. Low hematocrit
3. Hyponatremia
4. Hypokalemia

## 8

{username}

A 56-year-old male presents to the ER with abdominal pain and vomiting. He underwent splenectomy for trauma in the past. Similar incidents in the past resolved without surgical intervention. Currently, he is not passing gas or defecating.

Which of the following imaging tests will most likely advance the decision regarding the diagnosis?

1. Acute abdominal X-ray
2. Abdominal US
3. Chest X-ray while standing
4. Abdominal MRI

## 9

{username}

An 18-year-old male sustained abdominal trauma from a bicycle handlebar following falling from a bicycle. He was diagnosed at the ER as suffering from significant pancreatic trauma.

What is true regarding the injury?

1. The most commonly injured anatomic area is the body of the pancreas.
2. The injury to the pancreas is typically isolated, without involvement of other organs.
3. Diagnosis is made through pancreatic-focused ultrasound.
4. Elevated serum amylase levels are necessary for diagnosis.

## 10

{username}

The duodenum removed along with the head of the pancreas in surgical resections for tumors in head of the pancreas. What is the reason?

1. Shared arterial blood supply between the head of the pancreas and duodenum.
2. Tumors in the head of the pancreas always invade the duodenal wall
3. The common bile duct passes through the pancreatic head and empties into the duodenum
4. Common lymphatic drainage between the pancreatic head and duodenum

## 11

{username}

Which of the following best describes the Z-line?

1. The transition from cuboidal to squamous epithelium at the rectoanal junction.
2. The transition from squamous to cuboidal epithelium at the gastroesophageal junction.
3. The junction of the rectus abdominis muscles with the linea alba in the abdominal wall.
4. The connection of the internal and external oblique muscles in the inguinal canal

## 12

{username}

What is the most common cause of small intestinal obstruction?

1. Primary tumor of the small intestine
2. Incarcerated hernia
3. Bezoar (food impaction in the intestine)
4. Post-surgical external adhesions

## 13

{username}

At the time of removing the surgical preparation during colectomy, intestinal content leaked onto the surgical wound. What is the definition of the surgical wound according to the CDC?

1. Clean
2. Clean contaminated
3. Contaminated
4. Dirty-infected

## 14

{username}

Which of the following patients is suitable for the bariatric surgery detailed for him/her?

1. A 47-year-old male, BMI = 37, without concomitant diseases, undergoing sleeve gastrectomy.
2. A 58-year-old female, BMI = 38, with renal failure, undergoing biliopancreatic diversion surgery.
3. A 12-year-old male, BMI = 41, without concomitant diseases, undergoing Roux-en-Y gastric bypass surgery.
4. A 41-year-old female, BMI = 31, with uncontrolled diabetes, undergoing lap gastric band surgery.

## 15

{username}

A 38-year-old male, otherwise healthy, presents with weakness and mild pallor. Laboratory results: iron-deficiency anemia, with recurrent events of hematochezia. Gastroscopy and colonoscopy are normal, no findings.

What is the next step in the diagnostic workup?

1. Exploratory laparoscopy
2. Video capsule
3. Barium enema
4. Gastric emptying study

## 16

{username}

What is the most effective treatment for esophageal variceal bleeding caused by portal hypertension?

1. Beta-blockers combined with Glypressin
2. Surgical ligation of the left gastric artery
3. Endovascular treatment with insertion of a catheter between the portal system and the venous system (Transjugular intrahepatic portosystemic shunt - TIPS)
4. Endoscopic treatment



## 17

{username}

Which intervention is most likely to reduce the risk of leakage at the digestive tract anastomosis?

1. Performing surgery when blood albumin levels are above 3.5 g/dL
2. Administration of biological treatment with bevacizumab up to a week from the date of surgery.
3. Administering steroids starting one week before surgery and continuing for at least one week postoperatively
4. Using an esophageal anastomosis rather than a small intestine anastomosis

## 18

{username}

What is the name of the hernia located in the medial area of the rectus muscle and the lateral linea semilunaris?

1. LUMBAR Hernia
2. LITTRE Hernia
3. AMYAND Hernia
4. SPIGELIAN hernia

## 19

{username}

Which extraintestinal symptom of Crohn's disease does not improve after bowel resection surgery?

1. Erythema nodosum
2. Ankylosing spondylitis
3. Uveitis
4. Pyoderma gangrenosum

## 20

{username}

What is the most common anatomical location for a peptic ulcer in the stomach?

1. The small curvature next to the incisura
2. The body of the stomach
3. The large curvature next to the fundus
4. Prepyloric region

## 21

{username}

Which bile duct disease is the central risk factor for developing cholangiocarcinoma in adults?

1. Choledocholithiasis
2. Primary sclerosing cholangitis
3. Chronic cholecystitis
4. Choledochal cyst

## 22

{username}

Which description best characterizes abdominal pain associated with pancreatitis?

1. Colicky pain (in waves)
2. Continuous pain
3. Pain radiating to the right shoulder
4. Pulsatile pain felt with each heartbeat

## 23

{username}

Which of the following is included in the principles of Damage Control Resuscitation?

1. Maintaining systolic blood pressure (BP) above 110 mmHg
2. Administration of at least 2 liters of crystalloids
3. Early administration of blood and blood products
4. Avoidance of drugs such as tranexamic acid

## 24

{username}

A 57-year-old female is diagnosed with invasive ductal carcinoma measuring 2 cm in the right breast. No axillary lymph node enlargement is detected on palpation. The patient is scheduled for surgery.

What is most correct regarding the planned surgical procedure?

1. There is no survival advantage to a modified radical mastectomy compared to radiation + lumpectomy.
2. A radical mastectomy is recommended over a modified radical mastectomy.
3. Preventative removal of the contralateral breast is performed in the same surgery due to her age.
4. The surgery requires complete removal of the axillary lymph nodes on the affected side.

**25**

{username}

Which bariatric surgery relies solely on a restrictive mechanism?

1. SLEEVE GASTRECTOMY
2. LAP BAND
3. ROUX EN Y GASTRIC BYPASS
4. DUODENAL SWITCH

**26**

{username}

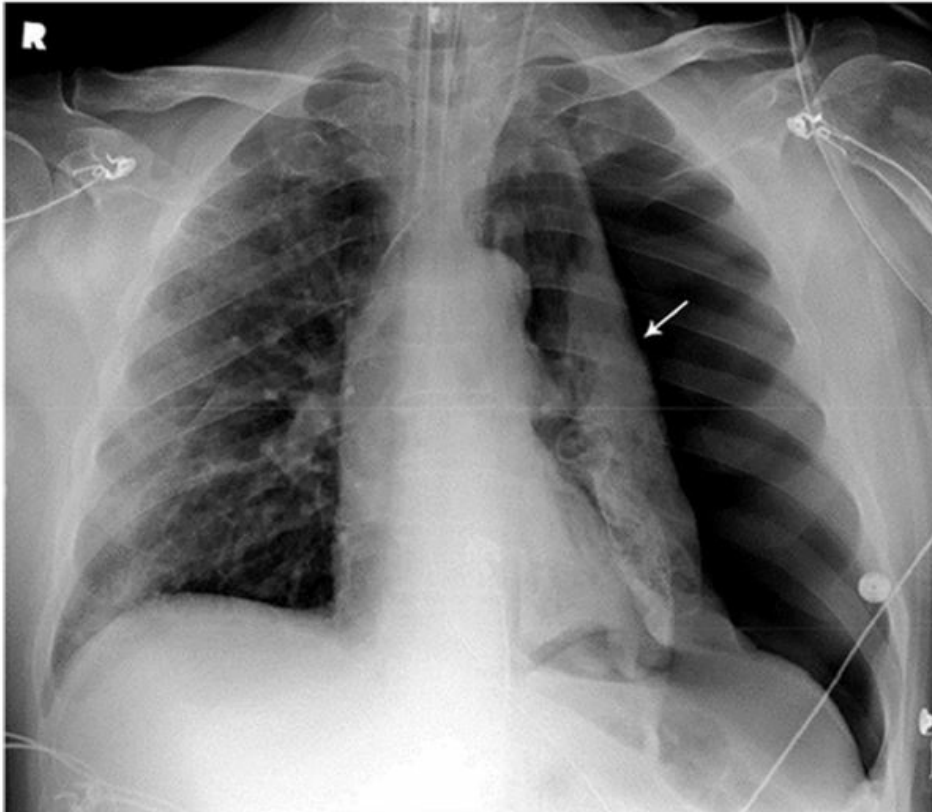
What is true regarding early acute postoperative bowel obstruction?

1. In more than 90% of cases, the obstructions are partial and will resolve spontaneously without surgery.
2. In most cases, obstruction after laparoscopic surgery is not connected to a specific point of transfer.
3. Surgery should be performed as soon as possible.
4. CT imaging does not aid in diagnosing the obstruction.

27

{username}

A 18-year-old male sustained a road traffic accident.  
On arrival, poor air entry on the left was noted, and he was intubated and ventilated on-site.  
A chest X-ray was performed upon arrival in the trauma room (attached).



What is the next step in managing the case?

1. Whole body CT
2. EXTENDED FOCUSED ABDOMINAL SONOGRAPHY IN TRAUMA
3. Needle insertion from the right side
4. Chest drain insertion, left side.

## 28

{username}

Which of the following patients has a definitive indication for surgery?

1. 25-year-old male after his first attack of sigmoid diverticulitis.
2. A 65-year-old male with diverticulitis of the right side of the colon
3. A 68-year-old male who has had two attacks of uncomplicated diverticulitis over the past two years
4. A 70-year-old male with sigmoid diverticulitis complicated by a fistula to the bladder that responded to antibiotics

## 29

{username}

Which of the following diseases is most commonly associated with primary sclerosing cholangitis (PSC)?

1. PSORIASIS
2. SYSTEMIC LUPUS ERYTHEMATOSUS
3. WEGENER GRANULOMATOSIS
4. ULCERATIVE COLITIS

## 30

{username}

Which of the following findings suggests grade 3 hemorrhagic shock in a trauma patient?

1. Elevated pulse pressure
2. Pulse rate of 105 per minute
3. Respiratory rate of 23 breaths per minute
4. Urine output of 8 cc in an hour

### 31

{username}

Which of the following benign tumors increases the risk of developing into colon cancer?

1. HAMARTOMA
2. INFLAMMATORY POLYP
3. SESSILE SERRATED POLYP
4. HYPERPLASTIC POLYP

### 32

{username}

What is the most common life-threatening complication of portal hypertension?

1. Acute Encephalopathy
2. Tense ascites
3. Esophagogastric Variceal bleeding
4. Hepatorenal syndrome

### 33

{username}

Which of the following benign bone tumors is considered the most aggressive?

1. OSTEIOD OSTEOMA
2. GIANT CELL TUMOR
3. ENCHONDROMA
4. OSTEOCHONDROMA

## 34

{username}

All of the following methods assist in evaluating pre-surgical risk, except for:

1. ASA
2. ACS NSQIP
3. MELD
4. SOFA

## 35

{username}

What is correct regarding the treatment of ischemic colitis?

1. An urgent catheterization is necessary in order to open the narrowed mesenterial artery
2. Most patients require surgical bypass of the narrowed artery, which resolves the issue without intest
3. Supportive treatment, including antibiotics, bowel rest, and fluids, results in improvement in most patients without surgery.
4. Following hemodynamic stabilization, surgical resection of the affected area is necessary.



## 36

{username}

A 20-year-old male combat soldier, otherwise healthy, is diagnosed with a right-sided inguinal hernia that does not interfere with daily functioning. What will be the medical recommendation?

1. Urgent surgery should be performed due to his role.
2. An abdominal CT scan should be performed to confirm the diagnosis before surgery
3. Elective surgery should be recommended in order to prevent complications related to the hernia.
4. Monitoring alone may be considered for asymptomatic hernias.

## 37

{username}

A 48-year-old female, usually healthy and with no significant medical history, undergoes surgery to remove a uterine fibroid due to vaginal bleedings. During the surgery, the surgeon identifies a 10 cm lesion in the right lobe of the liver, characterized by central fibrosis and radiating septa.

Which of the following diagnoses is consistent with a hepatic finding?

1. Focal nodular hyperplasia
2. Cholangiocarcinoma
3. Hemangioma
4. Liver adenoma

**38**

{username}

Which of the following benign conditions is the most common in the upper digestive tract?

1. Paraesophageal Hernia
2. Heartburn
3. Gastro-Esophageal Reflux disease (GERD)
4. Achalasia

**39**

{username}

A 23-year-old female presents to a surgeon after feeling a mass in her breast. On examination, a hard, mobile, non-tender mass is palpated, measuring 3 cm in diameter. What is the most likely diagnosis?

1. Cyst
2. Breast cancer
3. Hamartoma
4. Fibroadenoma

**40**

{username}

Various cells serve the body in healing of a wound.

Which of the following cells is the first to appear in a healing wound?

1. Neutrophils
2. Macrophages
3. Fibroblasts
4. Lymphocytes

**41**

{username}

Which of the following diverticulae is most likely caused by an inflammatory process or significant infection of lymph nodes?

1. Mid esophageal diverticulum
2. Epiphrenic diverticulum
3. Kommerell diverticulum
4. Zenker's diverticulum

**42**

{username}

Which of the following factors could delay early wound healing, and why?

1. Vitamin C deficiency causes delayed healing several days after injury.
2. Zinc deficiency delays healing primarily in cases of severe burns.
3. Excess iron - polycythemia - negatively affects wound healing.
4. Excess vitamin A impairs monocyte activation.

**43**

{username}

A 55-year-old female underwent imaging that raised suspicion of a neuroendocrine tumor of the pancreas. Which of the following blood markers would most strongly support the diagnosis if elevated?

1. Carcinoembryonic antigen (CEA)
2. Alpha-fetoprotein
3. Chromogranin A
4. CA19-9

**44**

{username}

Which of the following sentences is correct regarding breast ultrasound?

1. The test helps distinguish between solid and cystic lesions.
2. The test is the preferred routine screening test for breast cancer.
3. When added to mammography, the US reduces the likelihood of false positives.
4. It is less effective in women with dense breasts.

**45**

{username}

A 83-year-old male presents with an incarcerated groin mass.  
The precise anatomical margins of the mass are as following:

Upper margin - Iliopubic tract  
Lower margin - Cooper ligament  
Lateral margin - Femoral vein  
Medial margin - Lacunar ligament

Which type of hernia would you suspect when approaching the patient?

1. Direct inguinal hernia
2. Indirect inguinal hernia
3. Femoral hernia
4. Sliding hernia

**46**

{username}

All of the following findings are included in the ABCDE criteria for melanoma evaluation, except:

1. Color change to the lesion
2. Depth of the lesion
3. Irregular margin of the lesion
4. Change over time

**47**

{username}

Which of the following is the most common etiology associated with acute pancreatitis in children?

1. Gallstones in the bile duct
2. Medications
3. Blunt abdominal trauma
4. Excessive alcohol consumption

**48**

{username}

Which of the following is a risk factor for breast cancer?

1. Late first menstrual period
2. Late menopause
3. Multiple births
4. A full first pregnancy before the age of 18

**49**

{username}

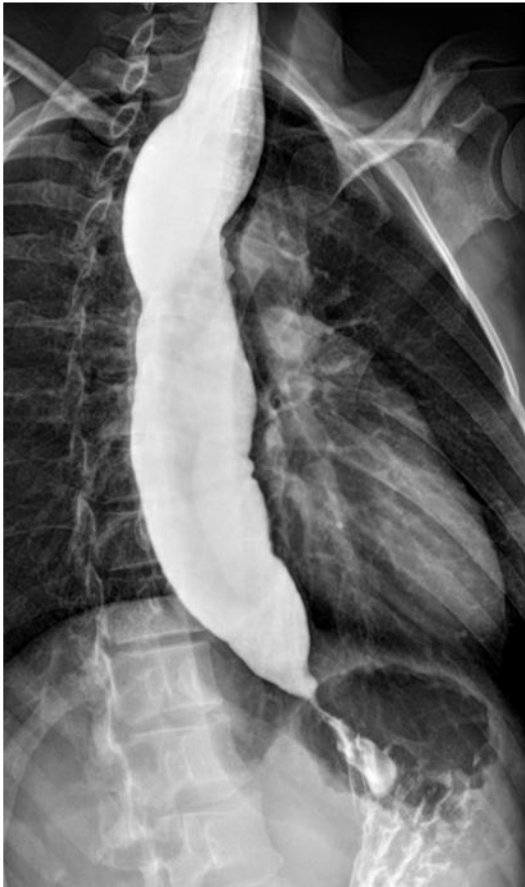Which compensation mechanism is activated first in response to vessel volume reduction due to significant blood loss?

1. Increased renal blood flow
2. Increase in parasympathetic inhibition
3. Increase in sympathetic activity
4. Increase in the intravascular compartment hydrostatic pressure

**50**

{username}

You are presented with an X-ray of the upper digestive tract that was performed with water-soluble contrast agent.



What is the gold standard test to verify the diagnosis of this disease?

1. Chest CT with oral contrast administration
2. Diluted Barium swallow X-ray.
3. Manometry
4. Gastroscopy



## 51

{username}

An 8-year-old male with newly diagnosed adrenal insufficiency has been treated with medications for the past few months. In the past year, there has been a decline in his academic performance, including concentration difficulties and behavioral issues. As part of an evaluation for new-onset seizures, a brain MRI was performed, revealing widespread lesions in the white matter.

Which laboratory test is likely assist in determining the child's diagnosis?

1. Serum 17-hydroxyprogesterone levels
2. 21-hydroxylase enzyme activity
3. Serum adrenal antibody levels
4. Serum long-chain fatty acid levels

## 52

{username}

A 3-year-old female is diagnosed with cleft palate, language delay, and motor delay. In the background, she has recurrent respiratory tract infections. Blood tests reveal hypocalcemia.

What is recommended as part of the follow-up for her likely diagnosis?

1. Liver function tests
2. Monitoring intraocular pressure
3. Platelet levels in the blood
4. Echocardiography

## 53

{username}

A 10-year-old male is referred for evaluation due to short stature. Since the age of two, his height has consistently been in the 5th percentile, while his weight is in the 20th percentile. The parents are in the 75th percentile for height. The father reported delayed shaving, starting at approximately 18 years of age. Upon primary investigation - X-ray of the hand shows a bone age consistent with 8 years. Extensive blood tests, including chemistry, complete blood count, celiac serology, and thyroid function, are all within normal ranges.

What is the most likely diagnosis?

1. Constitutional Delay
2. Familial Short Stature
3. Laron Syndrome
4. Growth Hormone deficiency

## 54

{username}

Which of the following is a risk factor for Sudden Infant Death Syndrome (SIDS)?

1. Poor socio-economic condition
2. Age between 6-8 months
3. Sleeping in a supine position
4. Female sex

{username}

A 10-year-old male presents with progressive muscle weakness that started about 5 days ago in the legs and continued to rise in the direction of the hands and the face. Around two weeks ago, he suffered from diarrhea, and since then has been complaining of increasing fatigue. The weakness progresses fast, and he struggles to hold objects in his hand and lift his legs from the bed. He is also complaining of dyspnea. On the examination, symmetrical weakness of the limbs, and weakened reflexes.

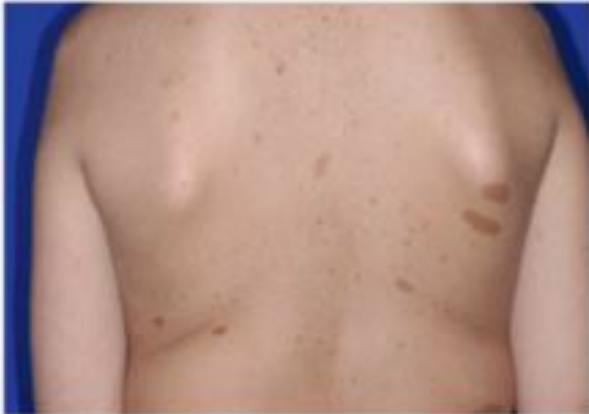What is the most appropriate treatment in this case?

1. Administration of active and passive immunization against the pathogen
2. Antibiotic treatment for the diarrhea
3. Only supervision and waiting for spontaneous recovery
4. Administration of intravenous immunoglobulins (IVIG)

**56**

{username}

A 5-year-old female presents with a complaint of loss of visual acuity. On examination, findings seen on the attached image are noted. The child's mother reports having similar findings.



What is the next step to be taken?

1. Brain imaging
2. Laser therapy.
3. Biologic therapy
4. Skin biopsy

**57**

{username}

An 8-year-old male has experienced fatigue and lower back pain following physical activity for the past year. Laboratory tests reveal normal levels of vitamin D, calcium, phosphorus, PTH and alkaline phosphatase. Bone density evaluation shows low bone mineral density. X-ray reveals a compression fracture of a lumbar vertebra.

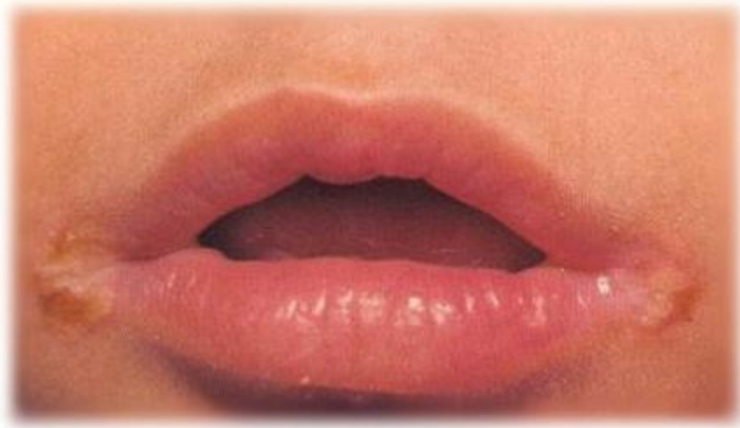What is the most likely diagnosis?

1. Hyperparathyroidism
2. Juvenile idiopathic osteoporosis
3. Osteogenesis imperfecta
4. Juvenile Idiopathic Arthritis

**58**

{username}

A 4-year-old male is being monitored for failure to thrive (FTT). Over the past 6 months, he has had lacrimation, eye infections with keratitis, seborrhea. Smooth tongue found on examination.



Which of the following deficiencies would be most likely to explain his condition?

1. Thiamine B1 (vitamin) deficiency
2. Riboflavin B2 (vitamin) deficiency
3. Retinol A (vitamin) deficiency
4. Tocopherol E (vitamin) deficiency

**59**

{username}

A 4-year-old male presents with a week-long history of fever and bloody diarrhea. Over the past day, he has become pale, weak, and lethargic. Laboratory tests reveal a clinical picture of acute kidney injury, anemia, and thrombocytopenia.

Which type of anemia is most consistent with his likely diagnosis?

1. Aplastic Anemia
2. Iron Deficiency Anemia due to GI Bleeding
3. Coombs Positive Hemolytic Anemia
4. Microangiopathic Hemolytic Anemia

**60**

{username}

A full-term newborn with a birth weight of 1900 grams and a head circumference below the 3rd percentile is under investigation. A brain ultrasound reveals periventricular calcifications. His diagnosis was performed via a PCR of a pathogen in the urine.

What is the most common complication for his likely diagnosis?

1. Sensorineural hearing loss
2. Early-onset cataract
3. Dental deformity
4. Aortic stenosis

**61**

{username}

A 4-month-old female presents to the emergency department following her first generalized seizure lasting approximately one minute. She has no prior neurological issues or family history of seizures. On examination of the child: her temperature is 39°C, she is fully conscious with a normotensive fontanelle, and the remainder of her examination is unremarkable.

What is the most appropriate next step in management?

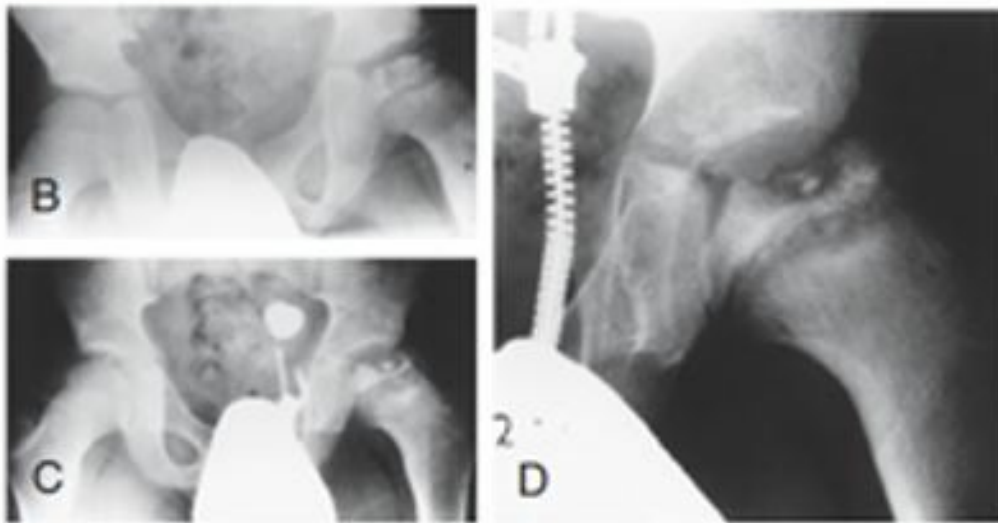1. Initiate antiepileptic therapy.
2. Administer antipyretics and monitor.
3. Perform a lumbar puncture to rule out meningitis.
4. Arrange for emergent neuroimaging.



{username}

An 8-year-old male presents with chronic hip and knee joints pain, especially after intense sports activity, with gradual worsening over the past week.

Physical examination reveals limited range of motion of the left hip joint, especially for internal rotation. The child is afebrile and has no additional symptoms. X-ray images attached.



What is the initial treatment recommendation for the most likely diagnosis?

1. Restriction of physical activity
2. Administration of calcium and vitamin D
3. Steroid therapy
4. Oral antibiotics

## 63

{username}

A 7-year-old male, about one month ago completed treatment with steroids for nephrotic syndrome, which had fully resolved. He was hospitalized now due to a recurrent event of generalized edema, protein +3 in urine dipstick, a low blood albumin level, and hyperlipidemia.

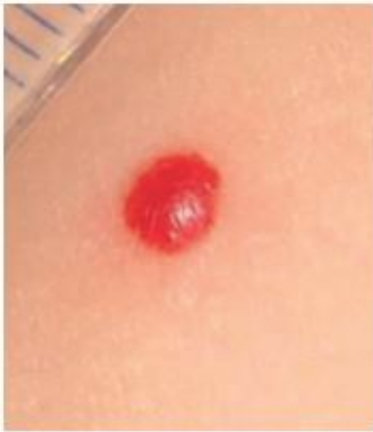What is the most appropriate management at this stage?

1. Steroid therapy should be started
2. A renal biopsy should be performed to guide treatment decisions
3. Fluid restriction alone
4. Cyclophosphamide therapy should be started

**64**

{username}

On examination after birth, a skin lesion was noted on a week-old infant's hand (image attached). During a follow-up examination, growth of the lesion was documented. Apart from this finding, the physical examination was normal, with no additional lesions.



What is the recommended management of the case?

1. Antibiotic treatment
2. Monitoring alone.
3. Treatment with calcium channel blockers
4. Surgical removal at 6 months old.

**65**

{username}

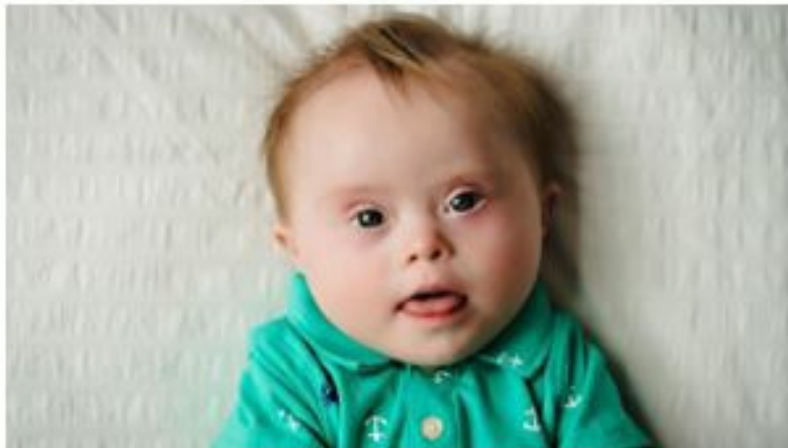Which of the following situations is an indication to perform a renal biopsy for a diagnosis of Post Streptococcal Glomerulonephritis?

1. Nephrotic-range proteinuria
2. Low C3 levels on presentation
3. Age under 5 years
4. Lack of a preceding clinical history of streptococcal infection

**66**

{username}

What is the most important reason for performing a chromosome test in a child suspected of having Down syndrome?



1. To confirm the clinical diagnosis
2. To identify translocations
3. To rule out another genetic syndrome
4. To identify mosaicism

**67**

{username}

A baby is referred to the ER after an episode of apnea accompanied by cyanosis. Which of the following conditions is consistent with the definition of a high-risk Brief Resolved Unexplained Event (BRUE)?

1. Birth at 34 weeks of gestation
2. Episode duration of about 30 seconds
3. General hypotonia observed during the event
4. Age of 7 weeks

**68**

{username}

A 14-year-old female presents with a two-month history of a cervical lymph node enlargement. She reports fatigue, slight weight loss, and night sweats. Treatment with antibiotics for 10 days did not improve the condition. On the physical examination, the lymph node is enlarged, hard, non-tender, and non-mobile. There is no redness or localized warmth. Laboratory findings include normal hemoglobin levels, mild leukocytosis, and elevated LDH levels.

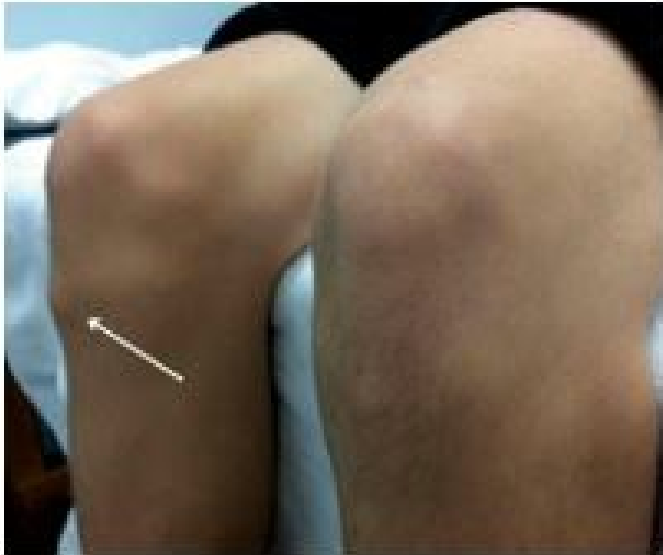What is the recommended next step in the investigation?

1. Bone marrow aspiration
2. Neck MRI
3. Biopsy of the lymph node
4. Observation only for an additional month

69

{username}

A 14-year-old male basketball player presents with bilateral knee pain localized below the patella. The pain worsens when running and jumping. Examination revealed the finding in the image.



What is the primary treatment recommendation?

1. Rest
2. Immediate surgery
3. Antibiotics
4. Steroid therapy

## 70

{username}

A 2-year-old male is brought to the ER after being found with an open bottle of toilet cleaner. The parents note that he has vomited several times since the incident, and he is complaining of abdominal pain and burning in the mouth. Upon physical examination, he exhibits drooling and tachypnea.

What is the most recommended immediate treatment in this case?

1. Urgent administration of active charcoal in order to neutralize the substance.
2. Administration of IV fluids and monitoring vital signs.
3. Urgent gastric lavage to remove the substance.
4. Administration of steroids to relieve the edema.

## 71

{username}

A 3-year-old male is evaluated in the emergency department after ingesting several antihypertensive tablets he found on table at home. On initial examination, the child is somnolent, with bradycardia and hypotension.

What is the most appropriate antidote for this condition?

1. Glucagon
2. Flumazenil
3. N-Acetylcysteine
4. Pyridoxine

## 72

{username}

A 5-year-old male suffers from a fever of 39.5°C for the past 6 days, accompanied by enlarged lymph nodes, a maculopapular rash, eye discharge, and cracked lips. On examination, he is restless. Blood tests reveal elevated ESR and hypoalbuminemia.

What is the most correct treatment in this case?

1. Start intravenous antibiotic treatment
2. Start intravenous antibiotic treatment in combination with steroids
3. Administer immunoglobulins (IVIG) and oral aspirin.
4. Administer IV fluids and antipyretic

## 73

{username}

A 6-year-old female arrives to the ER due to sudden-onset right hip pain, a week after a mild febrile illness. On examination, she avoids moving the leg, and the pain worsens with attempts to bear weight. Laboratory tests, including blood count and CRP, are within the normal range. Ultrasound reveals a small amount of clear fluid in the hip joint.

What is recommended treatment for the child's likely diagnosis?

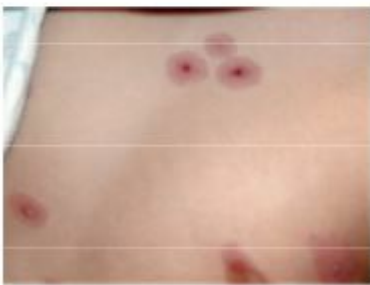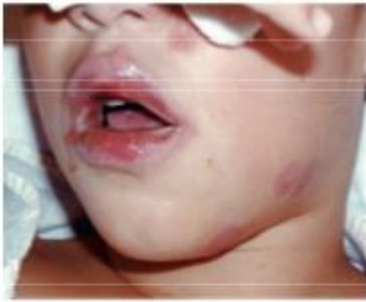1. Non-steroidal Anti-inflammatory drugs
2. Broad spectrum antibiotic treatment
3. Systemic steroidal therapy
4. Surgical intervention



**74**

{username}

11-years-old male, presents with a fever of up to 38.3°C and a dry cough lasting several days. Later, additional findings developed, as shown in the attached image. A recent blood count revealed new anemia.



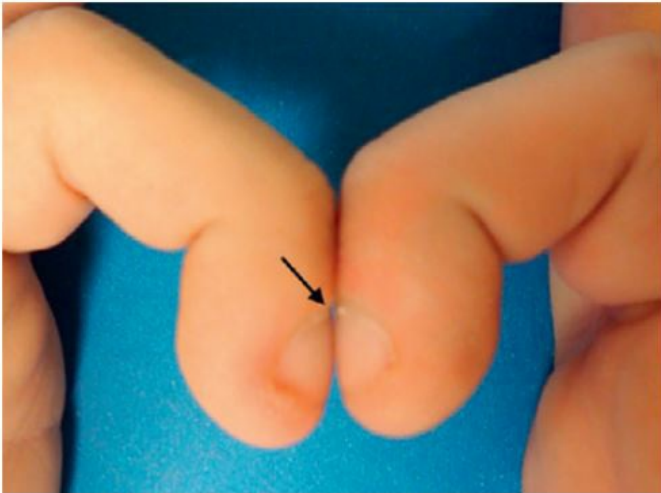
Which of the following infections is the likely cause of the disease?

1. Streptococcus pneumonia
2. Streptococcus pyogenes
3. Mycoplasma pneumonia
4. Hemophilus influenzae

75

{username}

In which of the following diagnoses can the phenomenon presented in the picture be observed?



1. Atopic dermatitis
2. Cyanotic heart disease
3. Turner Syndrome
4. Prader Willi

**76**

{username}

At a summer camp in South Israel, 20 children developed watery diarrhea requiring medical treatment and fluid administration. Roast chicken was served in the camp dining room the day before. Three weeks later, one of the children was hospitalized with weakness in the legs. On neurological examination in the ER, patellar reflexes were absent.

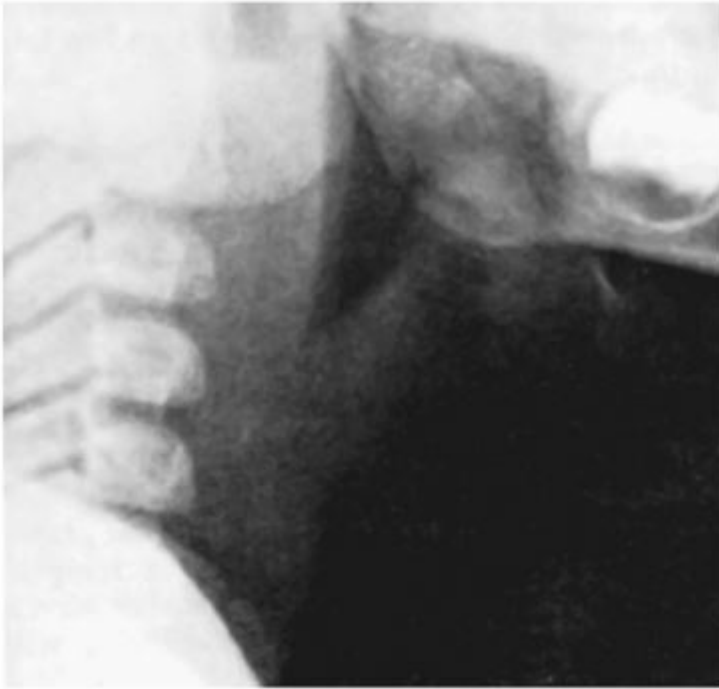Which of the following is the most likely cause of the outbreak?

1. Shigella dysenteriae
2. Salmonella Enterica
3. Norovirus
4. Campylobacter jejuni

**77**

{username}

A 5-year-old male, unvaccinated, presents with a high fever, sore throat, dysphagia, drooling, and progressive shortness of breath over the past few hours. Lateral examination of the neck was performed (image attached)



Which of the following is the most likely cause of his condition?

1. Respiratory syncytial virus
2. *Corynebacterium Diphtheriae*
3. *Haemophilus Influenza* type B
4. Parainfluenza virus

## 78

{username}

A 12-year-old male, participates in the school swimming team, complains of pain in the right ear. On examination, there is a thick, rubbery, yellowish discharge, along with edema and tenderness of the ear canal.

Which of the following pieces of information best supports the diagnosis?

1. Red, protruding, and inflamed eardrum.
2. Previous Streptococcus pneumonia infection
3. Vertigo on neurological examination
4. Frequent use of ear picks for cleaning of the canal

## 79

{username}

A 3-month-old male infant, with a history of normal pregnancy and birth, formula-fed, presents with frequent regurgitation, recurrent episodes of restlessness, and intermittently arches his upper body and tilts his head backward. The physical examination, including a neurological assessment, is unremarkable.

Which of the following treatments is suitable for his likely diagnosis?

1. Thickening of the formula
2. Switching to soy-based formula
3. Treatment with METOCLOPRAMIDE
4. Treatment with ORPHENADRINE

**80**

{username}

Which of the following drug-to-side effect matches is most correct?

1. Orange discoloration of urine - Rifampin
2. Optic neuritis - Rifampin
3. Ethambutol - Peripheral neuritis
4. Hyperuricemia - Ethambutol

**81**

{username}

A 2-week-old male presents to the ER with multiple episodes of vomiting, poor appetite, and weight loss since birth. On examination, he is pale, drowsy, and has hepatomegaly on abdominal palpation.

Laboratory results show hypoglycemia, and the urine test is negative for ketones.

What is the most likely diagnosis?

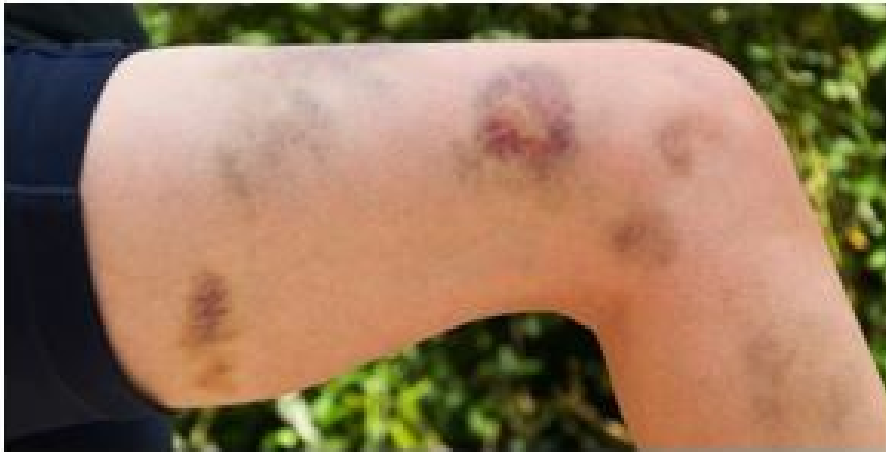1. Glycogen storage disease type 2 (Pompe)
2. Maple Syrup Urine Disease - MSUD
3. Glucose 6 phosphate dehydrogenase deficiency - G6PDD
4. Medium-chain acyl-coenzyme A dehydrogenase deficiency - MCADD

82

{username}

A 5-year-old male presents with findings as seen in the attached image.

On examination, he is in good general condition, without active bleeding, hepatosplenomegaly, or lymphadenopathy. No fever or pains. His parents deny any history of epistaxis or oral bleeding. On the blood count: platelet level of 25,000, with all other blood counts normal. Peripheral blood smear does not show blasts.



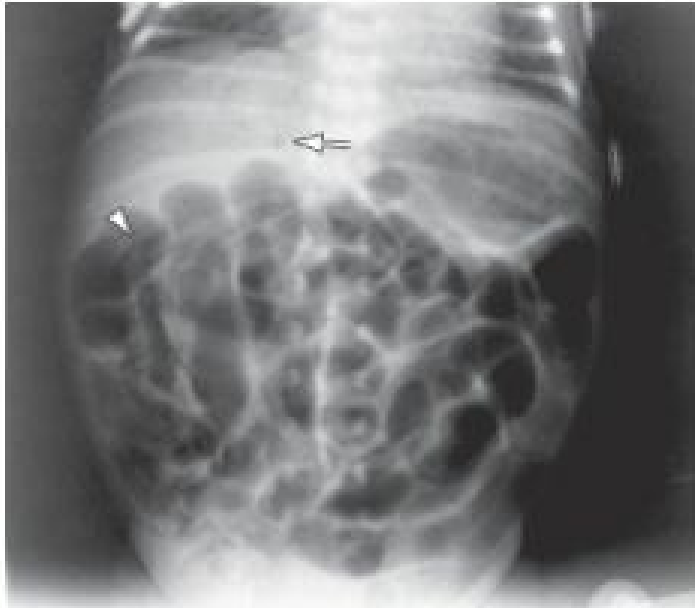
What is the next step in treating this child?

1. Intravenous steroid treatment
2. Treatment with immunoglobulins - IVIG
3. Clinical observation and strict avoidance of trauma
4. Treatment with Rituximab - Anti CD20

83

{username}

A premature neonate, born at 29 weeks of gestation, is now 14 days old. Has been drowsy for several hours and has a distended, tender abdomen. An abdominal X-ray was performed - see the attached image.



Which of the following is a protective factor for the baby's likely diagnosis?

1. Administration of probiotics
2. Exclusive breastfeeding
3. Caesarian Section
4. Use of anti-reflux formula



84

{username}

A 16-year-old male has blood pressure of 160/70 in the right arm.  
The following measurements were obtained from a cardiac catheterization:

Chamber	Saturation (%)	Pressure (mm Hg)
Superior vena cava	75	
Right atrium	75	8
Left atrium		10
Right ventricle	75	25/8
Left ventricle	100	160/10
Pulmonary artery	75	10/5
Ascending aorta	100	160/70
Descending aorta	100	100/80

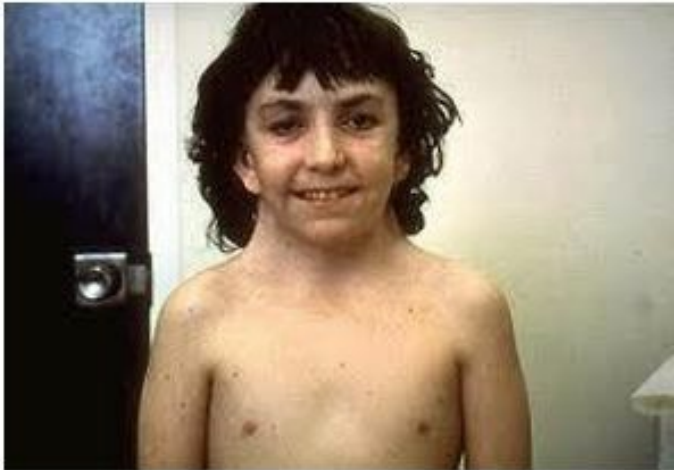Based on these data, what is the structural cardiac defect in this teenager?

1. Large secundum atrial septal defect
2. Moderate ventricular septal defect
3. Coarctation of the aorta
4. Aortic valve stenosis

85

{username}

A 12-year-old female presents with short stature, wide chest, and lack of pubertal development (image attached).



Which of the tests is most likely to be included as part of her monitoring?

1. Fecal calprotectin test
2. Slit-lamp eye examination
3. Heart echocardiogram and blood pressure measurement in all four limbs
4. Pulmonary function test after bronchodilator

**86**

{username}

A 13-year-old male has been experiencing epigastric pain for several months, which worsens after eating. The symptoms are accompanied by nausea, and his stools are black. He reports medicinal treatment prior to the onset of symptoms.

What is the most likely cause of his condition?

1. METRONIDAZOLE
2. IBUPROFEN
3. CLARITHROMYCIN
4. OMEPRAZOLE

**87**

{username}

Which laboratory finding characteristic of hypocalcemia is typically observed in hypoparathyroidism?

1. Elevated alkaline phosphatase levels
2. Elevated phosphate levels
3. Elevated vitamin D levels
4. Elevated magnesium levels

## 88

{username}

A 2-month-old solely breastfed male is evaluated for mucus and occasional small amount of blood in the stool. The infant appears well, afebrile, and gaining weight appropriately. The mother rules out vomiting, rashes, shortness of breath, or restlessness. No allergy is known in the family.

What is the most appropriate initial step in managing the case?

1. Test for milk and soy allergy in the baby.
2. Discontinue breastfeeding and switch to soy formula.
3. Continue breastfeeding, with the mother avoiding dairy and soy in her diet
4. Discontinue breastfeeding and switch to hydrolyzed (hypoallergenic) formula.

## 89

{username}

15-year-old female is hospitalized due to a one-week history of fever. Initially, she experienced conjunctival erythema, chills, and myalgia. On physical examination, a maculopapular rash is noted. During hospitalization, her symptoms initially resolved but later the fever recurred, accompanied by jaundice and thrombocytopenia. Her history includes a trip to streams in northern areas about three weeks prior to admission. In the second week of hospitalization, a pathogen was identified in her urine.

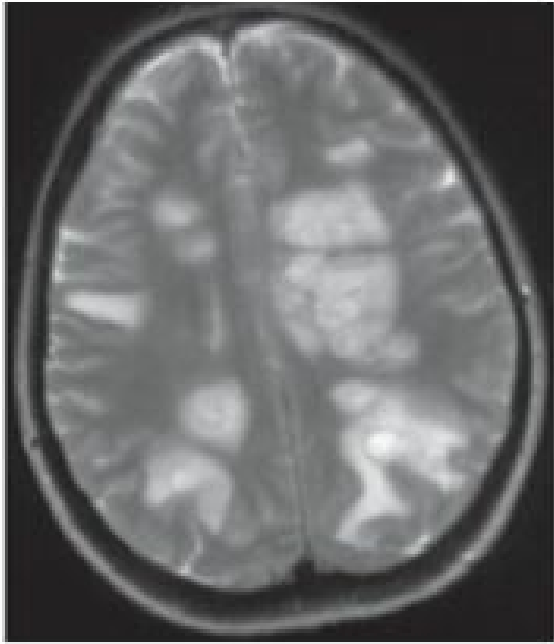
Which pathogen is most likely responsible for her illness?

1. *Rickettsia conorii*
2. *Leptospira*
3. *Legionella*
4. *Naegleria fowleri*

90

{username}

A 6-year-old female had fever and myalgia one week ago. She now presents with decreased level of consciousness, limb weakness, and gait instability. A brain MRI shows findings presented in the attached image.



What is the recommended treatment at this stage?

1. Broad-spectrum antibiotic treatment.
2. Administration of high-dose of steroids.
3. Fluids, Acamol and monitoring only.
4. Administration of fresh frozen plasma

## 91

{username}

A 4-year-old female is brought to the clinic by her parents, who report excessive thumb sucking, particularly before bedtime and during rest. The child is otherwise healthy, with no additional behavioral concerns. Normal physical examination.

What is the most suitable treatment recommendation at this stage?

1. Use of bitter-tasting creams to discourage thumb-sucking
2. Ignoring the behavior and encouraging alternative activities
3. Referring for behavioral psychological therapy
4. Immediate orthodontic intervention

## 92

{username}

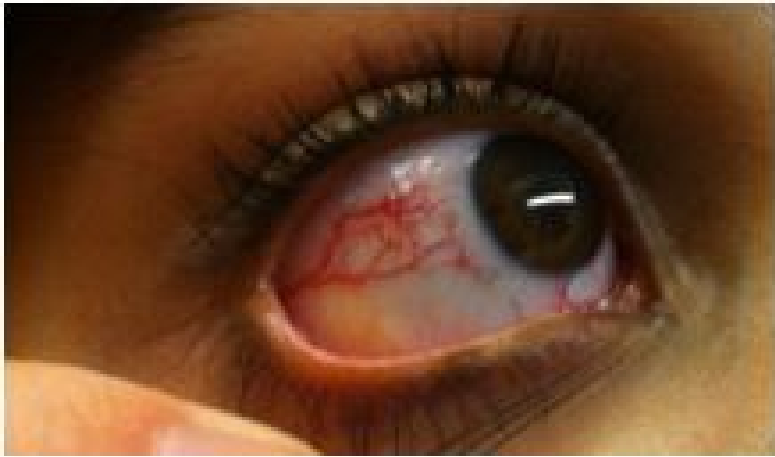Which of the following findings is more common in ulcerative colitis than in Crohn's disease?

1. Mouth ulcers
2. Erythema Nodosum
3. Toxic megacolon syndrome
4. Perianal involvement

93

{username}

A 3-year-old male is under follow-up due to ataxic gait, two prior pneumonias, and abnormal eye findings (image attached).



Which test should be avoided during further evaluation?

1. Chest X-ray
2. Lumbar Puncture (LP)
3. Suprapubic Aspiration (SPA)
4. Abdominal Ultrasound

## 94

{username}

An 8-year-old female presents with severe bilateral headache. The headache is associated with nausea and photosensitivity. The patient's mother reports that the episodes often occur after nights of poor sleep. There is no history of vomiting or awakening due to pain.

What is the recommended initial treatment in this case?

1. Immediate referral to the ER
2. Administration of steroids.
3. Administration of Amitriptyline
4. Administration of Ibuprofen.

## 95

{username}

A 2-year-old child is brought to the clinic with swelling around the eyelids. Laboratory tests reveal hypoalbuminemia with normal liver functions. Urine test shows no evidence of proteinuria.

What is the most likely diagnosis?

1. Nephrotic syndrome
2. Acute Glomerulonephritis
3. Protein losing enteropathy
4. Allergic reaction



{username}

A 4-year-old male presents two weeks after a viral upper respiratory tract infection. On examination, he was afebrile, respiratory rate of 40 breaths/min, an irregular heartbeat with gallop rhythm, systolic murmur (2/6) at the heart apex, and hepatomegaly in the abdominal examination. Apart from that, the examination was unremarkable.

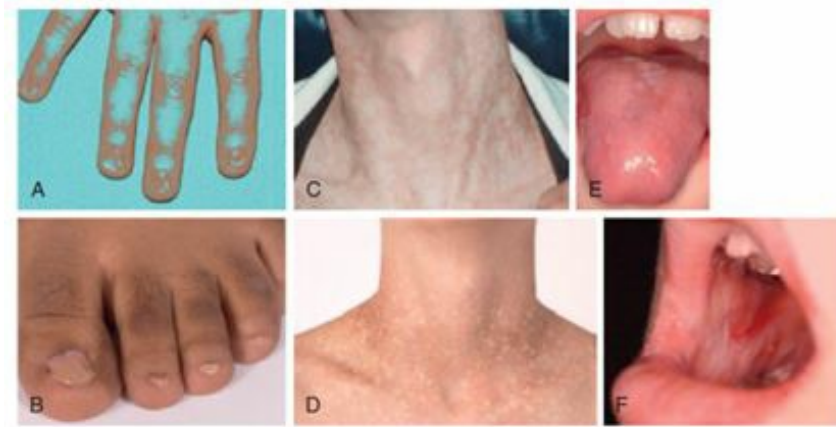What is the most likely diagnosis?

1. Infective endocarditis
2. Acute rheumatic fever
3. Viral myocarditis
4. Paroxysmal atrial fibrillation

{username}

A 10-year-old male presents to the clinic with fatigue, pallor, and recurrent epistaxis and gingival bleeding. In the background, there is a history of ongoing epiphora, recurrent pneumonia, and short stature.

On examination, he is missing eyelashes, and the findings shown in the image are observed:



Results of the laboratory tests:

Normal values	Measured value	
10.5-14	9.1	Hgb
5500-15000	2500	WBC
1500-8400	900	Neut.
150K-450K	23000	PLT

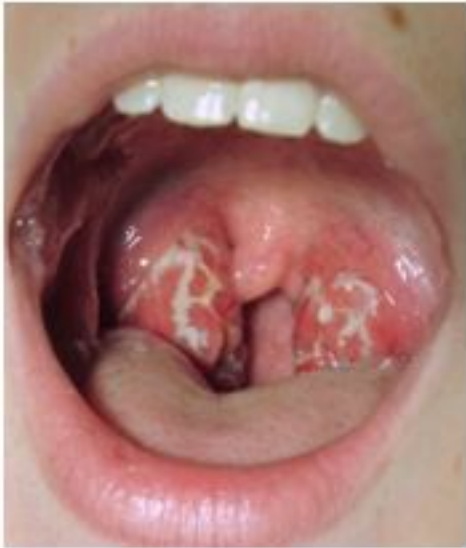Which of the following is a characteristic complication of the child's illness?

1. Liver cirrhosis
2. Renal insufficiency
3. Cardiac arrhythmias
4. Acute myeloid leukemia

**98**

{username}

A 6-year-old male, healthy and vaccinated, presents to the clinic with a fever and sore throat. On physical examination, the following was found, as shown in the image.



What is the recommended management of the case?

1. Start empirical treatment with Amoxycillin
2. Encourage hydration and provide analgesics
3. Perform a throat swab and initiate antibiotic therapy based on results
4. Refer to an ENT specialist for tonsillectomy

**99**

{username}

A 1-week-old male, born at home. Presents to the clinic with vomiting, hypotonia, generalized weakness, and refusal to eat since 2 days old. In the past day, he has shown poor suckling and reduced responsiveness to stimuli. The parents report his urine has a sweet odor.

Which test is likely to advance the diagnosis?

1. Long-chain fatty acid levels in the blood
2. Urine ketone levels
3. Amino acid levels in the blood
4. Isoforms of transferrin in the blood

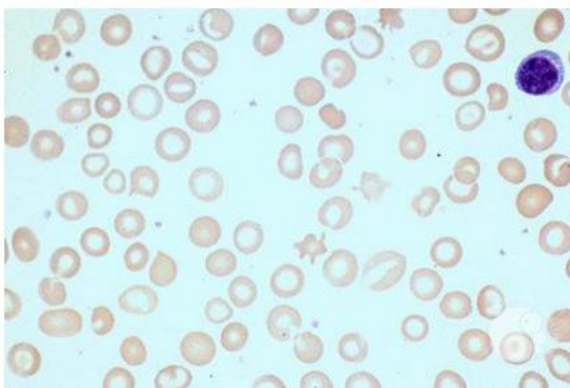
100

{username}

A 15-month-old male underwent a routine blood count showing the following:

Normal values	Measured value	
10.5-14	8.2	Hgb
70-85	68	MCV
2.7-4.9	3.1	RBC
13-16	18	RDW

On examination, there is no dysmorphism or hepatosplenomegaly. A peripheral blood smear was taken, results attached:



Which of the following scenarios could explain his condition?

1. First exposure to fava beans
2. Excessive consumption of cow's milk
3. High-carbohydrate diet
4. Over-supplementation with vitamin D