

## AHA SCIENTIFIC STATEMENT

# Cardiovascular Management of Aortopathy in Children: A Scientific Statement From the American Heart Association

Shaine A. Morris, MD, MPH, Vice Chair; Jonathan N. Flyer, MD; Anji T. Yetman, MD; Emilio Quezada, MD; Elizabeth S. Cappella, APRN-NP; Harry C. Dietz, MD; Dianna M. Milewicz, MD, PhD; Maral Ouzounian, MD, PhD; Christina M. Rigelsky, MS, CGC; Seda Tierney, MD, FAHA; Ronald V. Lacro, MD, Chair; on behalf of the American Heart Association Council on Lifelong Congenital Heart Disease and Heart Health in the Young (Young Hearts); Council on Cardiovascular and Stroke Nursing; Council on Peripheral Vascular Disease; Council on Cardiopulmonary, Critical Care, Perioperative and Resuscitation; and Council on Cardiovascular Surgery and Anesthesia

**ABSTRACT:** Aortopathy encompasses a spectrum of conditions predisposing to dilation, aneurysm, dissection, or rupture of the aorta and other blood vessels. Aortopathy is diagnosed commonly in children, from infancy through adolescence, primarily affecting the thoracic aorta, with variable involvement of the peripheral vasculature. Pathogeneses include connective tissue disorders, smooth muscle contraction disorders, and congenital heart disease, including bicuspid aortic valve, among others. The American Heart Association has published guidelines for diagnosis and management of thoracic aortic disease. However, these guidelines are predominantly focused on adults and cannot be applied adeptly to growing children with emerging features, growth and developmental changes, including puberty, and different risk profiles compared with adults. Management to reduce risk of progressive aortic dilation and dissection or rupture in children is complex and involves genetic testing, cardiovascular imaging, medical therapy, lifestyle modifications, and surgical guidance that differ in many ways from adult management. Pediatric practice varies widely, likely because aortopathy is pathogenetically heterogeneous, including genetic and nongenetic conditions, and there is limited published evidence to guide care in children. To optimize care and reduce variation in management, experts in pediatric aortopathy convened to generate this scientific statement regarding the cardiovascular care of children with aortopathy. Available evidence and expert consensus were combined to create this scientific statement. The most common causes of pediatric aortopathy are reviewed. This document provides a general framework for cardiovascular management of aortopathy in children, while allowing for modification based on the personal and familial characteristics of each child and family.

**Key Words:** AHA Scientific Statements ■ aneurysm ■ aorta ■ aortic diseases ■ bicuspid aortic valve disease ■ Ehlers-Danlos syndrome, Type IV ■ Loeys-Dietz syndrome ■ Marfan syndrome

**A**ortopathy encompasses a spectrum of conditions predisposing to dilation, aneurysm, dissection, or rupture of the aorta and other blood vessels. Although most literature focuses on adults, aortopathy is diagnosed commonly in children, from infancy through adolescence. Pediatric aortopathy primarily affects the thoracic aorta, with the most common pathologies being bicuspid aortic valve (BAV) and connective tissue disorders. Involvement of other segments of the aorta and the peripheral vasculature varies by specific condition.

Genetic testing, noninvasive imaging, medical therapy, and surgery are commonly used in the care of these children. However, published evidence to guide care is limited, and pediatric practice varies widely, likely because aortopathy is etiologically heterogeneous, with genetic and nongenetic conditions.<sup>1</sup>

The American College of Cardiology and American Heart Association published guidelines for the diagnosis and management of thoracic aortic disease in 2010 and 2022.<sup>2,3</sup> These guidelines are predominantly focused on

Supplemental Material is available at <https://www.ahajournals.org/journal/doi/suppl/10.1161/CIR.0000000000001265>

© 2024 American Heart Association, Inc.

Circulation is available at [www.ahajournals.org/journal/circ](http://www.ahajournals.org/journal/circ)

adults and cannot be applied adeptly to growing children, who have emerging features, growth and developmental changes, including puberty, and different risk profiles compared with adults. Although sufficient level I evidence is not yet available to produce guidelines for children, observational and epidemiologic studies have been published. To optimize care and reduce variation in management, experts in pediatric aortopathy convened to generate this scientific statement regarding the cardiovascular care of children with aortopathy.

This document provides a general framework for management of aortopathy in children, allowing for modification on the basis of personal and familial characteristics of each child. Consultation with a pediatric aortopathy specialist should be pursued in complex or severe cases, such as when the genetic diagnosis is unclear, or when escalation in medical therapy or surgical intervention is being considered. This scientific statement does not include Turner syndrome; the 2018 American Heart Association scientific statement on Turner syndrome covered its associated aortopathy.<sup>4</sup>

Along with cardiovascular evaluation, many children need other specialists, ideally as part of a multidisciplinary team that provides services in genetics, ophthalmology, pulmonary, orthopedics, podiatry, rehabilitation medicine, physical and occupational therapy, neurology, neurosurgery, gastroenterology, allergy, developmental pediatrics, psychology, and psychiatry. Detailed discussion of non-cardiovascular management is beyond the scope of this article. Smooth transition of care to a multidisciplinary adult aortopathy service is essential.

## EVALUATION OF THE CHILD WITH SUSPECTED AORTOPATHY

Heritable thoracic aortic diseases (HTADs) are a defined group of conditions under the aortopathy umbrella that are genetically mediated and predominantly involve the thoracic aorta. Timely diagnosis of HTADs can be lifesaving and allows for an accurate understanding of natural history, associated risks, and personalized management for the child and family. HTADs can be syndromic, such as in Marfan syndrome (MFS), with evolving multisystem features over the pediatric age range,<sup>5–14</sup> or nonsyndromic, without obvious external features, as seen in *ACTA2*-related HTAD. A list of HTADs with affected gene, inheritance, molecular pathway, and distinguishing characteristics is listed in [Supplemental Table 1](#). Each genetic disorder has its own natural history ([Supplemental Tables 1–3](#)). There is wide variability in childhood presentations, ranging from little or no aortic enlargement to severe pathology of the aorta and other vessels, with unique factors associated with higher risk in each condition (Table 1).<sup>15</sup> Genetic testing can often confirm a diagnosis, ensuring disease-specific medical and surgical management of cardiovascular and noncardiovascular manifestations.

## History and Physical Examination

The history and physical examination of a child with suspected aortopathy should be comprehensive, with specific focus on craniofacial features and the cardiovascular, ocular, skeletal, integumentary, and neurologic systems (Figure 1 and [Supplemental Tables 1–3](#)).<sup>11</sup> Many children with aortopathy present with syndromic features, but others, particularly young children, may have subtle or emerging features or normal physical examination results.<sup>16–18</sup> Ectopia lentis is highly specific for MFS, whereas children with other forms of HTAD may have other distinctive features that can be helpful in diagnosis, such as iris flocculi, mydriasis, or Moyamoya-like cerebrovascular disease (*ACTA2*), or craniosynostosis or cleft palate/bifid uvula (Loeys-Dietz syndrome [LDS]). Serial evaluations including history and physical examination are essential because many associated features are dependent on age.

## Family History

Detailed family history with a pedigree of  $\geq 3$  generations is an important tool, given the wide variability in age at presentation and penetrance for HTAD.<sup>19</sup> Emphasis should be placed on any cardiovascular issues in the family, such as congenital heart disease, aortic valve disease, aneurysms or stenoses of the aorta and arteries, age and size of the aorta at the time of cardiovascular events, unexplained sudden death, premature stroke or myocardial infarction, and systemic findings that could be related to HTAD (Figure 1).

## Highlights: Evaluation of the Child With Suspected Aortopathy

- Evaluation for suspected aortopathy in a child should include a detailed history, physical examination, and family history of  $\geq 3$  generations, focusing on cardiovascular and extracardiac findings.
- Normal physical examination results or negative family history does not rule out a genetic aortopathy.

## IMAGING CONSIDERATIONS

Transthoracic echocardiography (TTE) is the primary imaging modality used for diagnosis and surveillance in children with aortopathy. A framework to determine frequency of routine clinical follow-up with imaging is presented in Table 2. More frequent imaging may be indicated on the basis of individual findings and the presence of high-risk features (Table 1). For children, the American Society of Echocardiography Guidelines and Standards for Performance of a Pediatric Echocardiogram should be applied, including measuring maximal diameters of semilunar valves and vessels from inner edge to inner

**Table 1. High-Risk Presentations in Pediatric Aortopathy**

Diagnostic group	High-risk features*
All	Family history of aortic dissection, especially in aorta with diameter <5 cm Family history of aortic surgery or dissection or rupture in childhood Aortic valvar dysfunction, moderate or greater Rapid aortic growth ( $\geq 0.8$ cm/y before 2 y of age, $\geq 0.5$ cm/y after 2 y of age, $>0.3$ cm/y for 2 consecutive y once adult height is reached) Pregnancy
Marfan syndrome	Early-onset Marfan syndrome, often but not always associated with variants in <i>FBN1</i> exons 23–32 Marked arterial tortuosity (vertebral artery tortuosity index $>50$ )†
Loeys-Dietz syndrome	<i>TGFBR1</i> or <i>TGFBR2</i> variants generally involve earlier age at onset and more severe presentation compared with other genes associated with Loeys-Dietz syndrome; <i>TGFBR2</i> R528 is associated with the worst prognosis <sup>5</sup> Among people with <i>TGFBR1</i> or <i>TGFBR2</i> variants, higher risk when any of these are present: craniosynostosis, cleft palate/bifid uvula, marked arterial tortuosity, widened scars, translucent skin Marked arterial tortuosity (vertebral artery tortuosity index $>50$ )† Female patients with <i>TGFBR2</i> variants and small body size
Vascular Ehlers-Danlos syndrome	Glycine substitutions or splice site variants‡ Vertebral artery tortuosity index adjusted for height $\geq 15.5$ † Frequent hematomas, frequent need for stitches or staples History of preterm delivery History of major arterial or organ event (eg, aortic or arterial dissection or rupture; intervention for aneurysm; intestinal, splenic, hepatic, bladder, or uterine perforation; pneumothorax) in patient or family member
ACTA2 variant	Smooth muscle dysfunction syndrome attributable to <i>ACTA2</i> R179 but also with other missense pathogenic variants Patent ductus arteriosus, Moyamoya-like cerebrovascular disease
PRKG1 variant	All affected patients have a risk for dissection as early as adolescence with minimal or no dilation
EFEMP2 variant	Cutis laxa, type IB is a rare, autosomal recessive condition presenting in early infancy with severe dilation, elongation, tortuosity, and narrowing of the aorta and systemic and pulmonary arteries and airway obstruction

\*In the presence of high-risk features, more aggressive management should be considered, including more frequent monitoring, additional use of cross-sectional imaging, escalation of medical therapy, exercise modification, and earlier surgical intervention.

†A vertebral tortuosity index calculator is available at <https://clarityregistry.com/calculators/risk-calculators/vti-calculator>.<sup>7,8</sup>

‡A glycine substitution with valine does not appear to be as high risk as other glycine substitution variants. Some splice site sequence variations are predicted to cause decreased collagen and therefore would be classified as low risk. For a list of specific sequence variations, see Pepin et al.<sup>15</sup>

edge in systole (Supplemental Figure 1).<sup>20,21</sup> Recommended TTE reporting in pediatric aortopathy is listed in Supplemental Table 4.

In pediatrics, echocardiographic and cross-sectional measurements are normalized by body size, most

commonly body surface area.<sup>21,22</sup> A Z score indicates the number of standard deviation units above (positive Z score) or below (negative Z score) the expected mean value for that structure and body surface area. By convention, aortic root and ascending aortic dilation are defined by a Z score  $>2$  SD. Severity classifications of dilation by Z score are listed in Table 2. Previous publications have used different measures to define severity of aortic dilation. The grading scale presented in this scientific statement is new, based on expert consensus of the writing committee, and devised in an effort to align clinicians. Different Z score calculations are available for pediatric populations (Supplemental Table 5).<sup>22</sup> The same nomogram should be used for serial measurements. The most commonly used nomograms in the United States are from Boston Children's Hospital and the Pediatric Heart Network.<sup>23,24</sup>

When presented with an aortic root or ascending aortic Z score  $>2$  SD, one must ascertain whether the aorta is truly dilated. Potential sources of error when calculating Z scores include inaccurate height or weight, population-inappropriate Z score calculator, and measurement technique. At extremes of height and weight, the Z score may be erroneous, because the existing calculators are derived from children with normal distributions of weight and height<sup>25</sup> (eg, with severe growth restriction, there may be a high Z score in the absence of true aortic dilation).

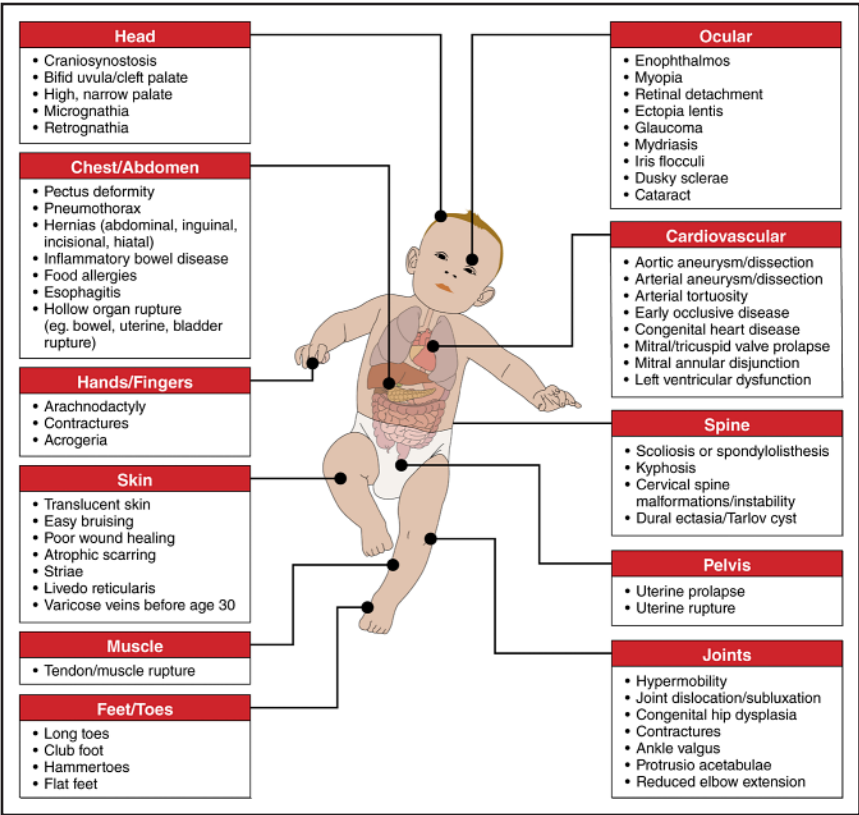
Transesophageal Echocardiography

Transesophageal echocardiography is essential for intraoperative assessment and comprehensive evaluation of true versus false lumen within dissected aortas before and after repair. Transesophageal echocardiography is an alternative imaging modality for suspected dissection when computed tomography angiography (CTA) is not definitive.<sup>20</sup>

Cross-Sectional Imaging

When TTE does not allow for satisfactory images of the heart and aorta, when considering surgical intervention, or in conditions at high risk for extravascular disease, cross-sectional techniques (ie, magnetic resonance imaging [MRI] or magnetic resonance angiography [MRA], CTA) provide excellent assessment of the aorta and peripheral vasculature and additional information about arterial and aortic tortuosity and dissection (Supplemental Table 6 and Supplemental Figure 2). Indications for cross-sectional imaging in pediatric aortopathy are listed in Supplemental Table 7.

Aortic measurements have been shown to be larger and more reproducible by MRI compared with TTE.<sup>26</sup> Multiple measurement techniques of the aortic root have been reported (Supplemental Figure 2A).<sup>27</sup> For



**Figure 1.** Findings that may be present in children with aortopathy by organ system.

standardization and easy comparison across institutions, primary assessment of the aortic root ideally uses cineographic imaging in a short axis en face plane using double-oblique techniques. The 3 maximum sinus-to-sinus distances from inner edge to inner edge in systole should be measured, and the maximum of these considered the reportable aortic root dimension. MRI also allows for detailed assessment of atrioventricular valve function and ventricular size and function.<sup>29</sup> Given the lack of ionizing radiation, MRI should be prioritized over CTA when possible. Sedation is typically necessary for MRI in patients <9 years of age; for lower-risk HTAD, in which cross-sectional imaging is indicated, clinicians may wait until 3 years of age or use CTA to avoid the risks of sedation reported in infants and young children.<sup>28</sup>

CTA is highly sensitive for monitoring the progression of aortic disease, with indications and measurements similar to MRI. CTA should be ECG-gated, and aortic measurements should be performed using double-oblique techniques. CTA is the optimal imaging modality for emergent evaluation of aortic dissection. When spinal hardware, pacemakers, or other implanted devices interfere with MRI, CTA may be indicated, although MRI may be reasonable when the interference is minimal or distant from the region being studied.

Although arterial tortuosity can be assessed qualitatively, quantitation can be performed from MRA or CTA

(Supplemental Figure 2E and 2F), including the vertebral artery tortuosity index (VTI) and the aortic tortuosity index.<sup>29,30</sup> Both VTI and aortic tortuosity index have prognostic value, with higher values being associated with increased severity of aortic disease and risk for complications. A VTI >50 has been associated with earlier aortic surgery, aortic dissection, and death in MFS and LDS with *TGFBR1* or *TGFBR2* variants.<sup>29</sup> Height-adjusted VTI  $\geq 15.5$  has been associated with earlier arterial events in vascular Ehlers-Danlos syndrome (VEDS).<sup>31</sup> Aortic tortuosity index  $\geq 1.95$  has been associated with earlier aortic dissection and aortic surgery in MFS.<sup>30</sup>

Some genetic conditions carry a high risk for peripheral arterial abnormalities, and cross-sectional imaging is indicated at regular intervals depending on the underlying genetic diagnosis and the presence and severity of vascular abnormalities on initial imaging.

### Fetal Echocardiography

Some features of HTAD can be identified in the fetus, including aortic root dilation and atrioventricular valve disease.<sup>32,33</sup> However, measurement of the fetal aortic root is not standard and should be specifically performed with appropriate Z scores (Supplemental Table 5). Extracardiac anomalies may also be noted, including diaphragmatic hernia (in MFS and LDS),

Table 2. Cardiovascular Imaging Intervals

Characteristics	Degree of aortic root or ascending dilation			
	None	Mild	Moderate	Severe
Age <16 y (Z score)	<2	≥2 and <3.5	≥3.5 and <5	≥5
Age ≥16 y (maximum dimension), cm	<3.5	≥3.5 and <4	≥4 and <4.5	≥4.5
Classic Marfan syndrome				
Early-onset Marfan syndrome	Imaging is driven by assessment of the atrioventricular valves, ventricular size, and function as much as by aortic dimensions; therefore, imaging frequency typically is every 1–3 mo, but may extend to every 6 mo with stable disease			
TGFBR1, TGFB2			*	*
TGFB2, TGFB3, SMAD2				*†
SMAD3	‡			*
Vascular EDS				*
Classic EDS	§			
ACTA2 (not R179)				*
ACTA2 (R179)			*	*
MYH11, LOX				*
MYLK	‡			
PRKG1			*	*
FLNA				
EFEMP2, arterial tortuosity syndrome	Rare; imaging is driven by specific cardiovascular lesions. More severe stenoses or dilation should be followed closely			
Bicuspid aortic valve (more frequent with AS or AR)	‡			
Dilated aorta or suspected HTAD with negative genetic testing and no other diagnosis	‡			
TGA, TAC, TOF, PA-VSD, Fontan	Based on underlying congenital heart disease			

Color code	
	Every 12–24 mo
	Every 12–18 mo
	Every 6–12 mo
	Every 3–6 mo

In the presence of high-risk features (see Table 1) or rapid aortic growth (≥0.5 and <0.8 cm/y before 2 years of age; >0.3 and <0.5 cm/y after 2 years of age), more frequent monitoring may be considered. Increased aortic growth rate may occur during puberty with somatic growth, so increased surveillance during this time may be considered. The first follow-up visit after diagnosis or transfer for imaging may be within a shorter time frame than described previously to assess the rate of growth. In addition, patients with congenital heart disease or young age may undergo more frequent assessment driven by lesion and age.

\*Surgery is recommended at aortic diameter of 4 to 4.5 cm based on gene and high-risk features (see Table 5).  
†Surgery is recommended in *TGFB3* if aortic diameter ≥5 cm (see Table 5).  
‡Imaging interval can be extended up to 36 months as these cases are generally milder.  
§If initial imaging has normal results, no follow-up is recommended.  
||At high risk for dissection beginning around age 17 years, even with minimal or no dilation.  
AR indicates aortic insufficiency; AS, aortic stenosis; EDS, Ehlers-Danlos syndrome; HTAD, heritable thoracic aortic disease; PA-VSD, pulmonary atresia with ventricular septal defect; TAC, truncus arteriosus communis; TGA, transposition of the great arteries; and TOF, tetralogy of Fallot.

contractures (in MFS), hypertelorism (in LDS), clubfoot (in VEDS), limb deficiency (in VEDS), and amniotic bands (in VEDS).<sup>32–34</sup>

Highlights: Imaging Considerations

- Z scores adjusted for body-surface-area allow for appropriate interpretation of aortic size in growing children. A Z score >2 SD defines dilation of both the aortic root and ascending aorta.
- TTE is the primary imaging modality used for diagnosis and surveillance.
- Baseline TTE should be performed to assess aortic dimensions, intracardiac anatomy, and ventricular function. Semilunar valves and vessels should be measured in systole from inner edge-to-inner edge.
- Indications for cross-sectional imaging (MRI or computed tomography) include need for better visualization of the aorta or other arteries, history of



or being at risk for extracardiac vascular disease, approaching surgical threshold, or ventricular dilation or dysfunction.

- MRI or CTA should use double-oblique techniques, measuring maximum sinus-to-sinus dimensions in systole, inner edge-to-inner edge.
- CTA is optimal to evaluate for aortic dissection.

## GENETIC TESTING, DIAGNOSIS, AND FAMILIAL EVALUATION

The role of genetic testing for aortopathy has expanded with greater recognition of the importance of a specific genetic diagnosis in risk assessment as well as medical and surgical management. Genetic testing should be targeted to those with the highest likelihood of confirming a diagnosis and those for whom a genetic diagnosis would affect clinical management. Figure 2 summarizes the indications for genetic testing in children with suspected HTAD.<sup>35,36</sup>

Multigene panels that include genes associated with HTAD are most commonly used; however, the genes included vary widely by laboratory. When there is a known familial pathogenic variant or when the clinical presentation strongly suggests a specific diagnosis, single gene testing can be used; for example, in the presence of ectopia lentis (lens dislocation), MFS associated with a variant in *FBN1* is most likely.<sup>3</sup> An HTAD panel may be considered for nonsyndromic presentations or in those with predominant systemic connective tissue findings. Broader testing (eg, whole exome sequencing) may be considered for early-onset and severe clinical presentations with features that are atypical for defined HTADs. Genetic testing should be initiated in the family member with the most severe and typical presentation. Overall, disease-causing variants are identified by genetic testing in 8% to 36% of individuals evaluated for thoracic aortic disease, with a higher yield in young children with syndromic manifestations.<sup>37–40</sup> Once a pathogenic or likely pathogenic variant is identified in one affected family member, cascade genetic testing of at-risk family members should follow. Family members without the familial variant do not need ongoing cardiac evaluation, and their offspring are not at increased risk for aortopathy.

Whenever genetic testing is offered, genetic counseling should be provided by a trained health care professional, ideally as part of a specialized aortopathy center.<sup>41–44</sup> Genetic counseling allows for the education of families regarding the benefits and limitations of genetic testing, as well as psychological, social, and ethical considerations. Genetic counseling also involves interpreting genetic testing results, identifying at-risk family members, and communicating with other family members. The genetic test result can lead to changes in management for the child and other family members, including the need for additional imaging to screen for

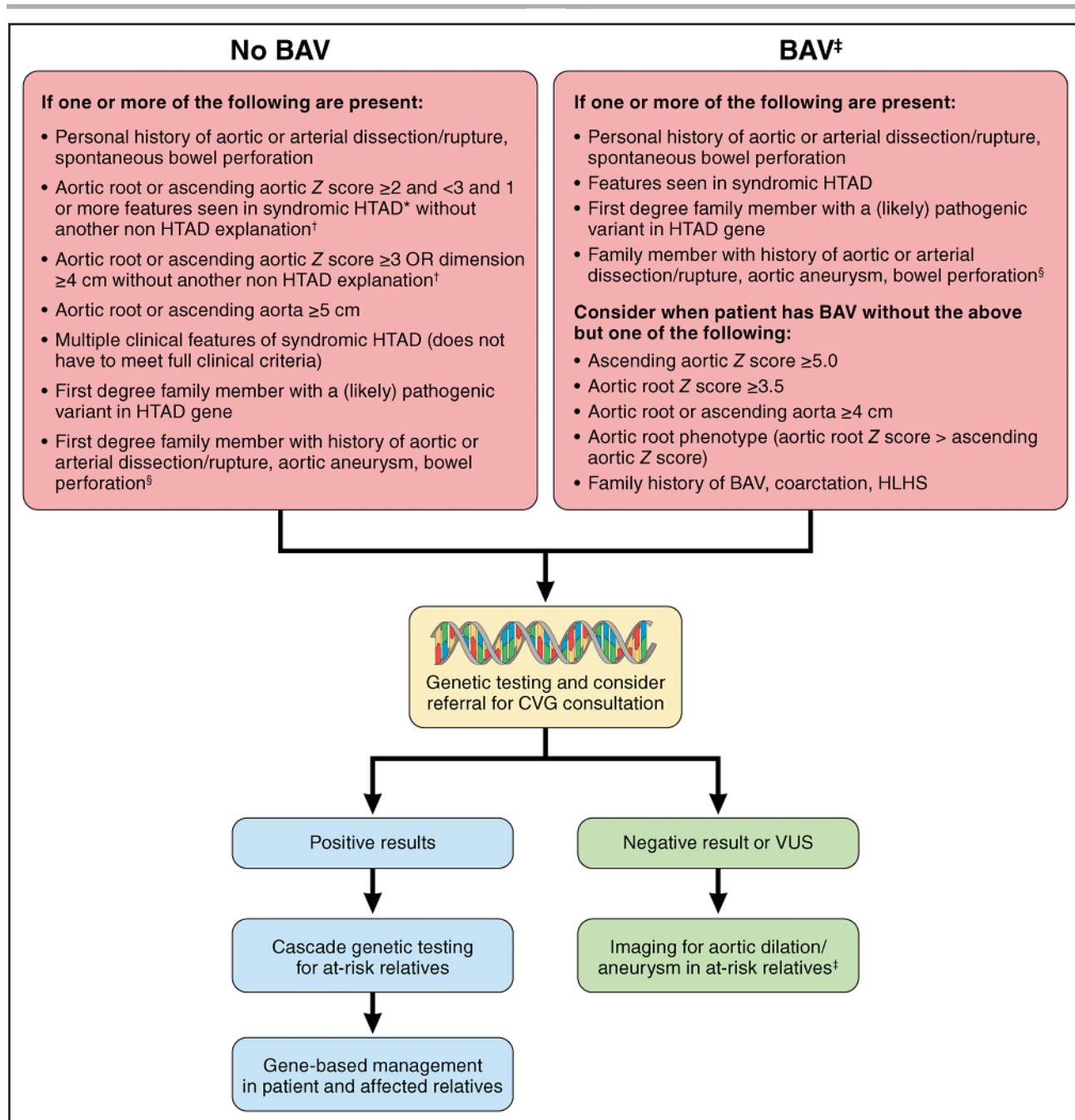
peripheral aneurysms, altered surgical thresholds, or the need for consultation with other specialists.

The American College of Medical Genetics and the Association of Molecular Pathologists have established guidelines for the interpretation of rare variants, with variants grouped into 5 categories: pathogenic, likely pathogenic, variant of uncertain significance, likely benign, and benign.<sup>43,50</sup> Pathogenic and likely pathogenic variants have sufficient evidence to support their role in triggering aortopathy and can therefore be used to identify other family members at risk. Variants of uncertain significance have limited or conflicting evidence that they are disease-causing, and should not be used to confirm or exclude a diagnosis in the person carrying the variant of uncertain significance or their family members. A wide range of variants are in this category and should be reassessed as data emerge over time.<sup>42,44,45</sup> Benign and likely benign variants are unlikely to cause disease. Consultation with a medical geneticist or aortopathy specialist is necessary for the proper interpretation of genetic testing results, particularly when a variant of uncertain significance is found. These variants require reevaluation over time as some will eventually be confirmed to be either pathogenic or benign.

If genetic testing fails to identify a cause, genetic testing is not pursued but aortic dilation is present, or BAV is present, noninvasive cardiovascular imaging screening of first-degree relatives should be performed. If the first imaging screening for family history of aortopathy is performed at a young age, a follow-up examination later in childhood may be considered. Additional information about aortic size in family members, particularly if aortic dilation is present or aortic dissection has occurred, provides information about the natural history of the familial aortopathy. Subsequent patient management in the absence of a genetic cause will depend on the cardiovascular presentation (see Aortic Dilation Attributable to Other Causes or Without Clear Genetic Cause).

## Highlights: Genetic Testing, Diagnosis, and Familial Evaluation

- Genetic diagnosis affects all aspects of clinical management. Genetic testing should be considered when there is reasonable likelihood of HTAD or when a specific genetic diagnosis might affect management (Figure 2).
- Whenever genetic testing is offered, formal genetic counseling should be provided by a trained health care professional.
- Once a likely pathogenic or pathogenic variant is identified, cascade genetic testing should be offered to at-risk family members.
- If genetic testing is negative, first-degree relatives should undergo imaging screening for aortic disease, and cascade imaging should be pursued if other family members are found to be affected.



**Figure 2. Evaluation and genetic testing algorithm for patients with suspected heritable thoracic aortic disease.**

\*Heritable thoracic aortic disease (HTAD) features can be seen in Supplemental Table 1. †Common non-HTAD associations with aortic root or ascending aortic Z score  $\geq 2$  include congenital heart block; chronic renal disease and hypertension; certain congenital heart defects (ie, truncus arteriosus, dextro-transposition of the great arteries, tetralogy of Fallot, pulmonary atresia with ventricular septal defect, single ventricle status post Fontan); very low weight for height or age; or single or erroneous measurement. ‡For patients with bicuspid aortic valve (BAV), aortic imaging in all first-degree family members should be performed regardless of genetic testing plan. §Especially when testing cannot be performed on the affected family member. CVG indicates cardiovascular genetics; HLHS, hypoplastic left heart syndrome; and VUS, variants of uncertain significance.

## MEDICAL THERAPY

The evidence supporting the use of pharmacologic therapy for aortopathy derive from randomized clinical trials (RCTs) of angiotensin receptor blocker (ARB) and  $\beta$ -blocker (BB) therapy in MFS.<sup>46–54</sup> Data on pharmacologic therapy for other causes of aortopathy are limited;

therefore, clinical experience from MFS is largely extrapolated to other aortopathies.<sup>55,56</sup>

The Pediatric Heart Network trial, the largest MFS clinical trial, compared losartan and atenolol in 608 children and young adults (age, 6 months to 25 years) with MFS and aortic root Z score  $> 3$  SD, and showed that atenolol (BB) and losartan (ARB) each reduced the rate

of aortic dilation, without significant difference between the 2 arms.<sup>48</sup> For each medication, the magnitude of benefit, as measured by reduction in Z score over a 3-year period, was greater in younger versus older patients, suggesting that medical therapy should be instituted even in the youngest children with aortic dilation. Both drugs were generally well tolerated and safe.

In a collaborative individual patient data meta-analysis including 7 RCTs in patients with MFS and no previous aortic surgery, ARB use reduced the rate of growth of the aortic root, including among those also taking a BB.<sup>54</sup> When using dual therapy, the dose of the first drug should be optimized to a therapeutic level before the addition and careful up-titration of the second drug, also to a therapeutic level, while monitoring for intolerance.

Pharmacologic therapy for patients with aortopathy and titration (Table 3 and Supplemental Table 8) should be tailored to the individual's characteristics, diagnosis, and risk profile. The goal of initiating therapy early in life is to slow aortic growth to delay surgery as long as possible; risk of aortic dissection may also be decreased or deferred to later in life. Hypertension should be treated aggressively.

Pharmacologic agents to avoid unless there are no acceptable alternatives include the following:

- 1) Agents that cause vasoconstriction, hypertension, or tachycardia, including excessive caffeine use and long-term use of decongestants, should be avoided. Triptan use has not been studied in HTAD, but given that triptans are vasoconstrictors, alternate treatment strategies should be exhausted before considering their use in patients with HTAD.
- 2) Fluoroquinolone antibiotics may exacerbate risk for aneurysm and dissection, and the US Food and Drug Administration advises avoiding these drugs for those with or at risk of aortic aneurysm.<sup>57–60</sup>
- 3) ARBs are teratogenic and should be avoided in pregnancy.<sup>61</sup>

Given the importance of functioning in school and other settings for children, and the success of both non-stimulant and stimulant medication in treating symptoms of attention-deficit/hyperactivity disorder, these medications should not be restricted for most children with aortopathy. Heart rate and blood pressure should be monitored closely.<sup>62–64</sup> There are animal data to suggest that calcium channel blockers may predispose to aneurysm and dissection<sup>65</sup>; however, there are not adequate human data to limit their use. Calcium channel blockers are often the mainstay of therapy for patients with renal disorders and hypertension. Further research is warranted among patients with HTAD.<sup>72</sup>

### Highlights: Medical Therapy

- Medical therapy for pediatric aortopathy is primarily derived from RCTs in MFS.

- Both ARBs and BBs have been shown to be safe and effective in slowing the rate of aortic growth.
- Medical therapy may be of greatest benefit if initiated at younger ages.
- Single and dual therapies may be considered; pharmacologic management should be individualized on the basis of personal and familial characteristics (Table 3).
- Fluoroquinolone antibiotics and agents that cause vasoconstriction, hypertension, or tachycardia should be avoided when possible.

### EXERCISE AND ACTIVITY

Exercise and activity considerations for children with aortopathy should promote safe and healthy cardiovascular lifestyle practices starting at a young age, emphasizing the positive contributions to physical well-being, emotional growth, and community building. Routine aortopathy evaluation should encourage discussion of safe exercise and activity practices, be reevaluated frequently in the context of age-appropriate risks and benefits, and be balanced continuously by shared decision-making between the physician and family.<sup>3,66–70</sup> Safe exercise and activity should also consider noncardiovascular issues, such as ectopia lentis (in MFS), risk for retinal detachment (in MFS and LDS), joint hypermobility (in MFS and LDS), cervical spine instability (in LDS), and increased susceptibility to internal organ and arterial perforation with minimal trauma (in VEDS).

Intense exertion raises concern for exacerbating aortopathy pathophysiology, because acute elevation in blood pressure induces aortic wall stress, further increasing risk for aortic dilation, aortic aneurysm, dissection, or rupture.<sup>3,71–73</sup> Adult aortopathy expert consensus guidelines primarily risk stratify activities by individual sport and physical component (eg, static versus dynamic), restricting most competitive athletics.<sup>2,3,66,67,71,74</sup> However, adult-based recommendations are challenging to apply to younger ages, and will likely over-restrict youth participation in sports.<sup>68</sup> Pediatric activity considerations should differ and extend beyond static versus dynamic profiles.<sup>3,71,72</sup> Table 4 provides age-appropriate guidance to help practitioners identify and address exercise practices by developmental stage (eg, mental and physical growth), scholastic and community or family expectations, personal risk-taking behaviors, and team and social pressures, and offer an earlier opportunity to learn healthy cardiovascular lifestyle practices.

A comprehensive pediatric aortopathy evaluation should be completed before sports or activity participation, including cardiovascular and noncardiovascular screening, with genetic and subspecialty consultations when appropriate. Underlying diagnosis and aortic size should be considered in counseling. Mild to moderate



**Table 3. Medical Therapy for Aortopathy**

Characteristics	Degree of aortic root or ascending dilation			
	None	Mild	Moderate	Severe
Age <16 y (Z score)	<2	≥2 to <3.5	≥3.5 to <5	≥5
Age ≥16 y (maximum dimension), cm	<3.5	≥3.5 to <4	≥4 to <4.5	≥4.5
Marfan syndrome	*			
TGFBR1 or TGFBR2	*			
TGFB2, TGFB3, SMAD3, or SMAD2	*			
Vascular EDS	See section on Vascular Ehlers-Danlos Syndrome			
Classic EDS				
ACTA2 (not R179)				
ACTA2 R179	††	‡	‡	‡
MYH11, LOX, MYLK				
PRKG1	†			
FLNA				
EFEMP2				
Arterial tortuosity syndrome		§	§	§
Bicuspid aortic valve			¶	¶
Dilated aorta or suspected HTAD with negative genetic testing and no other diagnosis		*		
TGA, TAC, TOF, PA-VSD, Fontan				#

Color code	
	No medication
	Single therapy
	At least single therapy, consider dual therapy (if tolerated)
	Dual therapy (if tolerated)**

In the presence of high-risk features (see Table 1) or moderately rapid aortic growth (≥0.5 and <0.8 cm/y before 2 y of age; >0.3 and <0.5 cm/y after 2 y of age), more aggressive medical therapy may be considered. Increased aortic growth rate may occur during puberty with rapid somatic growth; increased surveillance during this time may be considered for appropriate weight-based medical therapy. In presence of valvar disease or ventricular dysfunction, additional medications may be indicated.

\*Consider starting single therapy.

†Medical therapy, preferably β-blockers, should be considered in individuals in their early teenage years even in the absence of enlargement of the thoracic aorta to minimize the risk for both Type A and Type B dissection.

‡In ACTA2 R179, given hypotension and steno-occlusive disease, lower doses should be used initially, with close monitoring of blood pressure and symptoms.

§Patients are at risk of renal artery stenosis and stenoses in other arterial beds. Be aware of hypotension and hypoperfusion. Use caution with angiotensin receptor blocker therapy if renal artery stenosis is present.

||Includes bicuspid aortic valve caused by *NOTCH1* and *SMAD6* variants; does not include bicuspid aortic valve associated with other heritable thoracic aortic diseases (HTADs) listed in the table. When substantial aortic valve stenosis or regurgitation is present, the medication strategy may need to be altered to minimize risk to the coronary circulation.

¶Data are limited for use of medical therapy in bicuspid aortic valve with aortic dilation and include only a retrospective study of pediatric patients<sup>65</sup> with aortic Z score ≥4 and a survey of pediatric aortopathy programs.<sup>66</sup> The authors suggest that medical treatment for aortic Z score ≥4 is reasonable.

#May follow without medication depending on growth trajectory.

\*\*Dual therapy has only been systematically studied in Marfan syndrome.

EDS indicates Ehlers-Danlos syndrome; PA-VSD, pulmonary atresia with ventricular septal defect; TAC, truncus arteriosus communis; TGA, transposition of the great arteries; and TOF, tetralogy of Fallot.

cardiovascular effort, including in age-appropriate recreational sports, group activities, childhood play, and physical education, should be routinely encouraged, and may be cardioprotective.<sup>75</sup> Shared decision-making should begin in early childhood to help evaluate and mitigate potential risks of physical activity (eg, considering intensity, duration, location, and supervision). In general, lower-impact sports avoiding intense isometric exertion, and exercise that does not involve frequent or forceful Valsalva maneu-

ver (eg, heavy weightlifting), are considered safer.<sup>3,67,71,74,76</sup> Elite competition, training that requires sustained, intense exertion to the point of exhaustion, or activities that elevate the risk for bodily collision (eg, heavy contact sports, such as tackle football, hockey, or wrestling), trauma, or syncope are generally considered above the acceptable risk. Additional studies investigating safe exercise in pediatric aortopathy are warranted and would encourage physical activity among these patients.<sup>75</sup>

**Table 4. Exercise and Activity Considerations by Age, Diagnosis, and Intensity**

Consideration	Age 0–5 y (preschool)	Age 5–10 y (elementary school)	Age 10–14 y (middle school)	Age 14–18 y (high school)
Counseling				
	Introduce main concept of shared decision-making  Provide guidance and reassurance for exercise safety and organized athletics (moderate intensity); with routine supervision, general play is safe and strongly encouraged		Revisit shared decision-making process: discuss lifelong cardiovascular health habits  Help identify and encourage specific activities and team positions that decrease risk of exertion, collision, and repeated intense training  Explore safe outdoor recreational habits (eg, buddy systems)  Counsel regarding pediatric hypertension and obesity	Solidify shared decision-making process: identify and support lifelong cardiovascular health, help balance risks and benefits of desired activities, advise against high-risk adolescent behaviors (eg, substance abuse, smoking, vaping) and sedentary habits
Exercise and activity prescription				
Routine physical activity	Encourage regular childhood play (minimum 1–3 h/d)	Encourage regular moderate cardiovascular physical activity (30–60 min/d, 5 d/wk) as a healthy lifestyle choice		
Physical education	Encourage complete participation		Encourage routine participation; peak exertion activities discouraged (eg, rope climbing, timed sprints, push-up/pull-up competitions)	
Recreational sports	Encourage complete participation		Encourage routine participation with avoidance of contact sports (eg, tackle football, hockey, wrestling)	
Competitive sports		Competitive sports may be considered with regular risk/benefit discussions; avoid contact sports (eg, tackle football, hockey, wrestling) and high-intensity training, leagues, and competitions		
Amusement parks	Encourage full participation per size limitations	Caution may be warranted for high-intensity rides, including those with abrupt stops and starts in high-risk groups; use all proper safety equipment		
Intensity				
	Encourage developmentally appropriate childhood play	Encourage all age-appropriate recreational sports and group activities, including physical education class; frequent mild to moderate cardiovascular activity is safe and healthy		
			Guidance toward organized sports, certain team positions, and recreational activities with lower risk for bodily collision, physical trauma, strenuous training, or frequent unsupervised exertion	
			Avoid strenuous training and prolonged physical exertion, heavy weightlifting (requiring forceful Valsalva), and sustained exertion to exhaustion	
				Encourage lower-intensity varsity and junior varsity athletics, club sports participation  Refrain from more intense training or competition for highly select state or regional travel teams, Olympic development programs, collegiate varsity recruitment
Higher-risk criteria: diagnosis-specific considerations				
Marfan syndrome  Lens subluxation  Retinal detachment  Joint hypermobility	Loeys-Dietz syndrome  Joint hypermobility  Atlantoaxial instability	Vascular Ehlers-Danlos syndrome  Internal organ and arterial perforation with minimal trauma  Prone to dislocations  Avoid trampolines in addition to guidelines	FLNA deficiency  Extreme joint hypermobility	Bicuspid aortic valve  Moderate to severe valvular disease

	Low risk
	Low risk with modification as indicated
	Higher risk

All participants should be permitted normal restroom breaks, water, and rest upon request. In the presence of high-risk features (see Table 1), more aggressive management should be considered, including more aggressive exercise modification. In a group setting, appropriate replacement activities should be recommended to remain inclusive, especially in physical education and recreational settings. Standard protective equipment (eg, helmets, eye and mouth guards) should be encouraged and used when appropriate. Condition-specific considerations should be reevaluated frequently throughout all ages. Tailoring exercise counseling to the patient is encouraged in a shared decision-making model with additional guidance from aortopathy experts.

**Table 5. Surgical Thresholds for Children with Aortopathy**

Disorder or gene	Standard surgical threshold, maximum of aortic root or ascending aorta, cm	If high-risk features* are present, maximum of aortic root or ascending aorta, cm
Marfan syndrome	5.0 or maximum cross-sectional aortic area/height (cm <sup>2</sup> /m) ≥10, age ≥16 y†	≥4.5 cm For early-onset Marfan syndrome with severe dilation (when aortic valve annulus ≥2): <2 y: 3.3–3.4 ≥2 and <5 y: 3.7–3.8 ≥5 y: 4
<i>TGFB1</i> or <i>TGFB2</i>	≥4.5	When aortic valve annulus ≥2: <2 y: 3.3–3.4 ≥2 and <5 y: 3.7–3.8 ≥5 y: 4.0
<i>TGFB2</i>	≥4.5	≥4.5
<i>TGFB3</i>	≥5.0	≥5.0
<i>SMAD3</i> or <i>SMAD2</i>	≥4.5	≥4.5
<i>ACTA2</i>	≥4.5‡	≥4.2‡ Insufficient data in young patients with severe dilation, as often seen in smooth muscle dysfunction syndrome (R179 variants); consider using early Marfan syndrome numbers
<i>PKRG1</i>	§	§
<i>MYH11</i>	≥4.5	≥4.5
<i>MYLK</i>	Although events occur without dilation, no events have been reported in childhood; if considering surgery, discuss with aortopathy expert	Although events occur without dilation, no events have been reported in childhood; if considering surgery, discuss with aortopathy expert
<i>LOX</i>	≥5.0	Consider earlier intervention
<i>FLNA</i>	≥5.0	Consider earlier intervention
Vascular EDS	≥4.5	≥4.5
<i>EFEMP2</i>	None established; aggressive; consider using criteria for <i>TGFB1/2</i> with high-risk features	None established; aggressive; consider using criteria for <i>TGFB1/2</i> with high-risk features
Arterial tortuosity syndrome	≥5.0	NA (no dissections reported)
Dilated aorta without other diagnosis	≥5.0	≥4.5
Bicuspid aortic valve	≥5.5†	≥5.0
TGA, TAC, TOF, PA-VSD, Fontan	≥5.5–6.0	≥5.5–6.0
Previous Ross procedure	≥5.0–6.0¶	≥5.0–6.0

	Standard risk
	High risk

These thresholds are based on consensus agreement and published reports. Each case must be considered individually, and other factors (eg, need for surgery for other cardiovascular disease, aggressive family history, extremely rapid aortic growth) may necessitate modification of timing of surgery.

\*See Table 1.

†In patients who are substantially smaller or taller than average, surgical thresholds may incorporate indexing of the aortic root or ascending aortic diameter to patient body surface area or height or aortic cross-sectional area to patient height.

‡If cerebral blood flow is compromised, the higher perioperative stroke risk may warrant larger diameter aortic thresholds.

§Surgery recommended at age ≥17 years if there is any degree of dilation (Z score ≥ 2).

||In patients with bicuspid aortic valve undergoing surgical aortic valve repair or replacement, and who have a diameter of the aortic root or ascending aorta ≥4.5 cm, concomitant replacement of the aortic root, ascending aorta, or both is reasonable.

¶Institutional practice varies greatly. Given that Ross procedure is often performed in children with bicuspid aortic valve who may be susceptible to aortic dissection, threshold for surgery may be lower than in those with other congenital heart disease.

EDS indicates Ehlers-Danlos syndrome; PA-VSD, pulmonary atresia with ventricular septal defect; TAC, truncus arteriosus communis; TGA, transposition of the great arteries; and TOF, tetralogy of Fallot.

## Highlights: Exercise and Activity

- Age-appropriate, safe, and healthy exercise practices should be encouraged for all children with aortopathy, starting in early childhood.
- Pediatric exercise participation offers important opportunities for community building, teamwork, and a healthy cardiovascular lifestyle.
- Application of adult aortopathy guidelines will over-restrict youth exercise participation.
- Routine, ongoing counseling should involve shared decision-making; consider underlying diagnosis and cardiovascular findings, including aortic size; and evaluate type of activity and level of effort.
- Noncardiovascular HTAD manifestations, such as ectopia lentis, retinal detachment, joint hypermobility, cervical spine instability, and susceptibility to minimal trauma, need to be considered when defining safe exercise and activity.

## AORTIC DISSECTION AND PROPHYLACTIC AORTIC SURGERY

Aortic dissection in children is rare, but catastrophic. Type A dissection, involving the proximal aorta, is most often but not always preceded by aortic root or ascending aortic dilation, and elective repair of the aneurysmal aorta is life-saving. In contrast, acute Type B dissection often occurs in the absence of substantial dilation of the descending thoracic aorta. Management of aortic dissection is described in detail in the 2022 American College of Cardiology and American Heart Association guideline for the diagnosis and management of aortic disease.<sup>3</sup> Given the rarity of acute dissection or rupture in children, clinicians are referred to that document for comprehensive management.

As in adults, aortic size is the best predictor of Type A aortic dissection in children. Risk for dissection varies by genetic diagnosis, specific gene and pathogenic variant, severity of craniofacial features in patients with *TGFBR1* or *TGFBR2* variants, family history, degree of arterial tortuosity, aortic growth rate, and moderate or greater aortic insufficiency (Table 1).<sup>29,31,77,78</sup>

### Surgical Intervention in Children

Whereas Z scores are useful to guide imaging surveillance and medical therapy in children, absolute dimensions are primarily used to guide timing of surgical intervention for aortic root and ascending aortic dilation (Table 5). Commercially available aortic grafts cannot be used until the aortic annulus is  $\approx 20$  mm; both annular size and maximum aortic dimension should guide surgical timing.

Specific consideration should be given to whether the altered gene is known to cause Type A aortic dissection with minimal or no enlargement of the aorta or at a young

age. For example, patients with pathogenic *PRKG1* variants may be offered elective surgical repair with little to no aortic enlargement because aortic dissection can occur at normal aortic diameters. Patients with HTAD without identifiable genetic cause should be treated on the basis of the presentation and natural history in family members; if this information is not available, the patient should be managed as in classic MFS unless there are high-risk features (Table 1).

Care for aggressive aortic disease in children should be delivered at a specialized aortic center, incorporating shared decision-making and a personalized approach balancing aortic and surgical risk for each patient.

Elective replacement of the root and ascending aorta prevents Type A dissection and improves survival for patients with HTAD.<sup>79,80</sup> The entire ascending aorta should be replaced along with the root at the time of elective surgery for root aneurysms in all patients with HTAD. Selective replacement of the proximal arch (hemi-arch) may be both protective and safely performed by expert centers,<sup>81,82</sup> particularly for those with *TGFBR1* or *TGFBR2* variants or smooth muscle dysfunction syndrome attributable to *ACTA2* R179 variants,<sup>83</sup> although data to support this approach in all patients with aortopathy are lacking. Total arch replacement is not indicated for patients undergoing elective surgery for isolated root aneurysms, but could be considered for individuals with aggressive family history or high-risk genetic variants (eg, *ACTA2* R179 or *TGFBR2* R528).<sup>83</sup>

Surgical options to replace the aortic root include valve-sparing and valve-replacing approaches (Supplemental Figure 3). There are 2 techniques for valve-sparing root replacement: reimplantation of the valve, which has become the accepted standard, and aortic root remodeling, which preserves the physiologic flow in the sinuses. Reimplantation of the valve addresses all components of the pathologic root, including correcting and stabilizing annuloaortic ectasia, excising all pathologic root tissue, and correcting any associated aortic cusp abnormality, such as prolapse. Aortic root remodeling carries a higher risk for late annular dilation and aortic insufficiency if not supported by external annuloplasty. The dominant technique for preservation of the aortic valve in the pediatric population and patients with HTAD has been reimplantation of the aortic valve.

Benefits of valve-sparing root replacement include avoidance of valve-related adverse events (eg, anticoagulant-related hemorrhage, thromboembolic complications, endocarditis, reoperation). If the aortic valve is not salvageable, root replacement with a composite valved conduit should be considered. Indications for a bioprosthetic or homograft repair are limited given the predisposition for aggressive calcification in young children, limited durability, and challenges inherent to revision in the pediatric population. Valve-sparing options are limited if the aortic annulus is  $\leq 19$  mm. Both mechanical and bioprosthetic



valved conduits are possible. Root replacement with a pulmonary autograft is contraindicated in patients with aortopathy, except for those with BAV (in whom it is typically performed to address aortic valve dysfunction).

Several centers have reported excellent early and mid-term results of aortic root replacement in children.<sup>84–86</sup> The relative rarity of these interventions in children suggests that referral to a center with dedicated expertise may be advisable to optimize outcomes.<sup>87</sup>

Novel external aortic root support techniques (eg, Florida sleeve, personalized external aortic root support) have been reported as alternatives to replacement of the aortic root, but data in children are limited.<sup>84,85,88</sup>

### Highlights: Aortic Dissection and Prophylactic Aortic Surgery

- Aortic dissection in children is rare but catastrophic.
- Elective replacement of the aortic root and ascending aorta aneurysms is lifesaving.
- Elective root replacement includes valve-sparing and valve-replacing approaches.
- Timing of elective surgery is based on aortic dimension, genetic diagnosis, and presence of high-risk factors (Table 5).
- Surgical management should be directed by a specialized multidisciplinary aortic center.

## MARFAN SYNDROME

MFS is a multisystem connective tissue disorder caused by pathogenic *FBN1* variants with cardinal manifestations involving the ocular, musculoskeletal, and cardiovascular systems.<sup>89</sup> The estimated prevalence is 1:5000 to 10 000, and there is wide clinical variability in the number of systems involved and the severity of involvement of each manifestation, even within the same family. MFS is an autosomal dominant condition affecting female and male individuals with equal frequency, although male patients on average have a younger and more severe presentation.<sup>16</sup> All ethnic and racial groups are affected, but skeletal and systemic manifestations may be less common in Asian and Hispanic populations compared with White populations.<sup>17,18</sup> With prospective management, the life expectancy for affected individuals is similar to that of the general population.<sup>90</sup> Individuals with MFS should be managed by multidisciplinary care teams when possible.

Cardiovascular findings that lead to major morbidity and early death in MFS include dilation of the aortic root predisposing to aortic dissection and rupture, mitral and tricuspid valve prolapse and regurgitation, mitral annular disjunction, and left ventricular dysfunction. Dilation typically is predominantly at the aortic root (ie, sinuses of Valsalva). The age at onset and rate of progression of root dilation is highly variable. In MFS, one of the strongest predictors of aortic dissection is aortic root dimension.

Aortic dissection is extremely rare in childhood and rare in adolescence. Peripheral aneurysms are uncommon.

Mitral and tricuspid valve prolapse, with or without regurgitation, are common. Mitral annular disjunction is a distinct separation of the mitral annulus from the contiguous myocardium, can be diagnosed by echocardiography or MRI, and is associated with an increased risk of ventricular arrhythmias, but the implications of mitral annular disjunction warrant further research (Supplemental Figure 1G and 1H and Supplemental Tables 4 and 6).<sup>91</sup> Cardiomyopathy manifesting as ventricular dilation and dysfunction is seen in a subset of individuals and can occur independent of volume overload. Enlargement of the proximal pulmonary artery is common, but need for intervention is rare.<sup>97</sup>

Early-onset (previously called neonatal or infantile) MFS refers to a subset of cases in individuals who typically present as neonates with the most severe, progressive presentation, including cardiovascular, pulmonary, ocular, musculoskeletal, and diaphragmatic abnormalities. Cardiovascular manifestations include severe mitral and tricuspid valve prolapse and regurgitation, congestive heart failure, and progressive aortic root dilation. A scoring system based on history, physical, and genetic testing has been proposed to aid in diagnosis of early-onset MFS.<sup>92</sup>

## History and Physical Examination

Diagnostic criteria for classic MFS were defined in 2010.<sup>93</sup> Common findings in MFS that contribute to the systemic score are listed in Supplemental Table 9. Musculoskeletal findings include bone overgrowth and disproportionately long extremities and digits, scoliosis, and rib overgrowth leading to pectus excavatum and pectus carinatum. Ocular findings include ectopia lentis, myopia, and increased risk for retinal detachment, glaucoma, and early cataracts.

The systemic score can be useful in considering a clinical diagnosis of MFS, but has limitations when applied in children. Many children with MFS do not have sufficient features in early childhood to meet criteria using the systemic score because features accrue and worsen with age (Supplemental Figure 4).<sup>16,32</sup>

Genetic testing should be performed in children in whom MFS is suspected. A small percentage (<3%–5%) of individuals who meet clinical criteria for MFS will have negative genetic testing results. On the contrary, some children who meet clinical criteria for MFS will have another HTAD, particularly LDS, which has a distinct risk profile requiring different management.

## Imaging

Genetic Testing, Diagnosis, and Familial Evaluation and Table 2 provide a framework for baseline and surveillance imaging. A TTE should be performed at the time of

diagnosis to assess the aortic root, ascending aorta, and mitral valve; serial imaging is primarily based on aortic size. Annual TTEs are adequate for most children with MFS. Because peripheral aneurysms are uncommon, routine cross-sectional imaging is usually not necessary, except for indications listed in Imaging Considerations. MRA of the neck can provide a VTI, which can be helpful in risk assessment.

## Medical Therapy, Exercise, and Surgical Intervention

See Medical Therapy, Exercise and Activity, Aortic Dissection and Prophylactic Aortic Surgery, and Tables 3 through 5.

### Highlights: Marfan Syndrome

- Clinical diagnostic criteria for classic MFS have limitations in children. The MFS systemic score (Supplemental Table 9) is a useful screening tool for historical and physical findings suggestive of MFS, but should not be relied upon in isolation.
- Genetic testing should be performed in children suspected to have MFS; variants in *FBN1* are found in >95% of children with MFS.
- A TTE should be performed at the time of diagnosis and during surveillance. TTE provides adequate assessment of the aortic dimensions for most children. Frequency of serial imaging is driven by aortic dimensions and associated high-risk factors (Table 1).
- Cross-sectional imaging is indicated selectively in MFS (see Imaging Considerations).
- In RCTs, BBs and ARBs have been shown to reduce the rate of growth of the aortic root. Monotherapy or dual therapy should be considered depending on aortic root size.
- Aortic dissection is rare in children.

## LOEYS-DIETZ SYNDROME

LDS is a spectrum of conditions with involvement of the cardiovascular, craniofacial, skeletal, cutaneous, and immunologic systems.<sup>94</sup> The LDS spectrum is caused by heterozygous pathogenic loss-of-function variants in 6 genes encoding direct effectors of the transforming growth factor- $\beta$  cellular-signaling cascade: *TGFBR1*, *TGFBR2*, *SMAD3*, *TGFB2*, *TGFB3*, and *SMAD2* cause LDS1 through LDS6, respectively. As with all HTADs, clinical presentation and natural history vary dramatically between the genes as well as within variants in 1 gene.

Cardiovascular features that overlap with MFS include high risk for progressive aortic root dilation, type A dissection, and myxomatous degeneration of the mitral valve with prolapse and regurgitation. Both LDS and

MFS increase risk for Type B dissection, which may be preceded by only minor changes in aortic dimension, necessitating close surveillance particularly after surgical repair of the proximal aorta.

Features specific to LDS include a predisposition for aneurysms and dissections throughout the arterial tree, with frequent involvement of head and neck vessels, descending aorta, and superior mesenteric, celiac, and iliac arteries. Penetrance of other aneurysms is much lower than aortic events for all the LDS genes.<sup>77</sup> Arterial tortuosity is particularly frequent and severe in many forms of LDS, particularly in the head and neck. Unlike MFS and HTAD attributable to other genes, vascular events can occur in childhood, especially with *TGFBR1* and *TGFBR2* variants, but rarely, if ever, with *TGFB2*, *TGFB3*, or *SMAD3* variants, and can occur at relatively small vascular dimensions when compared with most other conditions.<sup>77,95</sup> Select forms of congenital heart disease (eg, BAV, patent ductus arteriosus [PDA], atrial septal defect) show increased frequency in LDS. Mitral annular disjunction may also occur in children with LDS.<sup>13</sup>

## History and Physical Examination

In LDS, there is considerable overlap in phenotype with other vascular HTADs, particularly MFS and VEDS (Supplemental Tables 1 and 2). Craniofacial features more commonly seen in LDS than others include craniosynostosis, hypertelorism, cleft palate/bifid uvula (but not cleft lip), exotropia, dusky sclerae, and extensive tooth discoloration and decay.

Cutaneous features seen in LDS include easy bruising, skin translucency with easily visible veins, dystrophic scar formation, persistence of facial milia past infancy and often into adulthood, eczema, and subcutaneous cysts. Skeletal features apart from those seen in MFS include club foot and cervical spine instability, which may progress to spinal cord injury without intervention. Allergic and autoinflammatory features in LDS include environmental and food allergies, anaphylaxis, asthma, eczema, and autoinflammatory gastrointestinal disease, including eosinophilic esophagitis, gastritis, colitis, and Crohn disease, although many patients have few or none of these complications.

## Imaging

Genetic Testing, Diagnosis, and Familial Evaluation and Table 2 provide a framework for baseline and surveillance imaging. A TTE should be performed at the time of diagnosis to assess for congenital heart disease, the aorta and valve, and ventricular structure and function (Supplemental Table 4); serial imaging is based on aortic size. The high predisposition for aneurysms beyond the aortic root in all forms of LDS mandates the use cross-sectional imaging (eg, MRA, CTA) from head to pelvis at the time

of diagnosis, although this may be delayed until later in childhood in milder presentations of LDS (eg, *TGFBR3*, *SMAD2*, *SMAD3*) unless the family history or specific variant warrants earlier surveillance. In young children, CTA is often used because of the speed of image acquisition to minimize or avoid sedation. The frequency of subsequent imaging will vary depending on the specific diagnosis and genotype, age, family and surgical history, symptoms or signs, and previous imaging findings.

## Medical Therapy

See Medical Therapy and Table 3.

There have been no RCTs of medical therapy in LDS. Current practice is based on mouse models of LDS and extrapolation from RCTs in humans with MFS. More aggressive medical and surgical therapy should be considered when there are high-risk features in an individual or family (Table 1). Among the 6 subtypes of LDS, the risk for aortic dissection varies by gene and specific variant, although there is considerable variability and overlap. Individuals with variants in *TGFBR1* or *TGFBR2* generally have earlier age at onset and more severe presentation compared with the other LDS genes. Among those with variants in *TGFBR1* or *TGFBR2*, risk is highest when high-risk features are present (Table 1).<sup>78</sup> *TGFBR2* variants that substitute histidine or cysteine for arginine at codon 528 (R528H/C) are associated with the worst prognosis, with most patients undergoing surgical intervention or presenting with dissection  $\geq 20$  years of age.<sup>77</sup>

There is no consensus regarding the optimal age for beginning medical therapy, but in the presence of moderate to severe aortic dilation, high-risk features (even with little or no aortic dilation), or a family history of severe aortic disease, initiation of medical treatment at the time of diagnosis should be considered, even in infancy.

## Exercise

In addition to general concerns about exercise and activity (see Exercise and Activity and Table 4), risk assessment in children with LDS should include risk of retinal detachment and spinal cord injury attributable to cervical spine instability. Regular physical activity contributes positively to emotional and physical health. Decisions regarding physical activity should be made using shared decision-making among the child, family, and health care professional, considering the child's personal risk profile.

## Surgical Intervention

See Aortic Dissection and Prophylactic Aortic Surgery and Table 5.

There is consensus that aortic root size thresholds for surgical repair should be somewhat smaller in LDS

than those typically used in MFS and some other HTADs (Table 5). Other factors that should be integrated into surgical decision-making include comorbid events that could influence outcome and the assessment of risk versus benefit for the individual and family. Within the LDS spectrum, the thresholds for surgical repair vary depending on the natural history of each condition and presence of high-risk features (Table 1), generally  $>4.0$ – $4.5$  cm for all subtypes except *TGFBR3* ( $>5.0$  cm).<sup>3</sup>

Surgical outcomes are similar to those observed in MFS, without evidence for excessive tissue fragility, although emerging reports suggest the potential for increased risk of anastomotic dehiscence, pseudoaneurysm, or formation of vascular fistulae at the site of repair in a subset of severely affected children with variants in *TGFBR1* or *TGFBR2*.<sup>96</sup> Dissection or aneurysm may occur distal to the repair site, and sequential replacement or repair of involved segments may be needed.<sup>97,98</sup> As in other HTADs, coronary button aneurysms can be seen, with rare progression to a size warranting reintervention.<sup>85</sup>

The thresholds and approaches for repair of aneurysms or dissections in vascular segments distant from the aortic root are largely based on expert opinion rather than rigorous studies, although the practice of avoiding intravascular stents in native tissue unless needed as a temporizing measure appears both broadly accepted and defensible through experience.

## Highlights: Loeys-Dietz Syndrome

- Clinical presentation is highly variable in children. A pathogenic or likely pathogenic variant in one of the LDS genes is usually present.
- TTE and cross-sectional imaging from head to pelvis should be performed at baseline and during surveillance.
- Serial imaging is driven by gene, variant, associated risk factors (Table 1), and findings at baseline.
- It is reasonable to treat children with LDS with an ARB or BB, or both.
- Compared with MFS, congenital heart disease is more common, risk for aortic dissection is higher, and involvement of the distal aorta and peripheral arteries is more common.
- Surgical thresholds for aortic dimensions in LDS tend to be smaller than for MFS.

## VASCULAR EHLERS-DANLOS SYNDROME

VEDS, previously Ehlers-Danlos syndrome (EDS) type IV, is a rare autosomal dominant HTAD caused by variants in *COL3A1* that encode part of type III collagen.<sup>34</sup> The prevalence of VEDS has been estimated at 1:50 000 to 150 000, which may underestimate the true prevalence.<sup>34</sup> The variant is inherited in  $\approx 50\%$  of cases; 50% of cases are de novo.

Bruising and skin lacerations are the most common adverse events in children. Dissection and rupture of the aorta and other arteries, pneumothorax, and hollow organ perforation are the highest-risk events.<sup>15</sup> Approximately 20% of affected individuals experience an aortic or arterial event  $\geq 20$  years of age.<sup>99</sup> Death  $>20$  years of age is more common in male patients (male:female ratio 3:1).<sup>34</sup> Stratifying risk factors are presented in Table 1. Dissection and rupture can occur in almost any medium or large artery, but most commonly occur in the carotid or vertebral arteries. VEDS is the most common known genetic cause of spontaneous coronary artery dissection.<sup>100</sup>

## History and Physical Examination

Affected individuals most frequently present with a history of abnormal bruising or other VEDS-related events, or with a family history of VEDS or VEDS-related events. VEDS may be diagnosed incidentally on genetic testing for other indications, but this is rare.<sup>44</sup>

Children often have subtle or no dysmorphic features, and the diagnosis is often delayed or missed. Common features include translucent skin with easily visible veins, which is more difficult to appreciate in those with dark skin, deep-set eyes with dark circles under the eyes, a small, narrow nose, and thin lips. Skin may be soft and may easily bleed or bruise. Needing stitches or staples for minor injuries is common but not universal. Affected children commonly sleep with their eyes open. Other common findings include club or flat feet, small-joint hypermobility, and acrogeria. Other features are listed in [Supplemental Table 2](#). A pathogenic or likely pathogenic variant in *COL3A1* is necessary for diagnosis.

## Imaging

Approximately 15% of individuals with VEDS have dilation of the aortic root or ascending aorta<sup>31</sup>; however, aneurysm can occur anywhere in the arterial tree. Unlike in MFS and LDS, aortic or arterial dissection or rupture in VEDS often occur in the absence of aneurysm.<sup>100</sup> Normal results on TTE or MRA or CTA do not rule out risk of an arterial event. However, presence of an aneurysm likely increases the risk of dissection or rupture.

Whether to conduct systematic imaging has been controversial because interventions have involved extremely high risk, although this observation was likely biased because intervention was used as a last resort.<sup>99</sup> In recent years, safer endovascular and surgical approaches for aneurysms and dissections have been developed.<sup>101</sup> Surveillance imaging to detect abnormalities now has the potential to improve survival. A French cohort instituting systematic arterial

imaging showed improved survival compared with previous eras, although further studies are warranted to confirm this finding.<sup>102</sup> A European survey of experts also reached a consensus favoring serial imaging in VEDS.<sup>103</sup> A suggested schedule for serial follow-up is given in Table 2, with guidance for cross-sectional imaging in [Supplemental Table 7](#). More frequent imaging can be considered in the presence of high-risk features (Table 1).

## Medical Therapy

The results of a single RCT suggested that the 3rd-generation BB celiprolol reduced adverse cardiovascular outcomes.<sup>55</sup> However, the study had several major limitations, and celiprolol is not available in the United States. No other agents have been studied systematically in humans.<sup>62</sup> Based on overlapping properties between celiprolol and other 3rd-generation BBs (eg, carvedilol, labetalol, nebivolol), some physicians have used one of these agents, regardless of the presence of aortic or arterial dilation or hypertension ([Supplemental Table 8](#)).<sup>104</sup> Extrapolating from RCTs in MFS, some clinicians have used ARBs in children with VEDS.<sup>104</sup> A retrospective cohort study of children and adults from the United Kingdom demonstrated that individuals receiving a long-term BB or ARB had fewer vascular events than those not on cardiac medication who received the same lifestyle and emergency care advice.<sup>104</sup> Given trial and observational data, treatment with a BB is reasonable, even in the absence of aortic dilation, or if not tolerated, an ARB may be considered, although further investigations are warranted. For patients with high-risk features (Table 1), therapy with BBs or ARBs may be more strongly considered. For medications to avoid, see Medical Therapy.

The use of vitamin C in doses ranging from 1 to 4 grams daily in adults has been advocated by some in an effort to decrease bruising and improve wound healing.<sup>105</sup>

## Exercise

Data on VEDS and exercise are primarily limited to case reports and surveys.<sup>106–108</sup> In addition to general concerns about exercise and activity (see Exercise and Activity and Table 4), risk assessment in children with VEDS focuses on hematoma, muscle rupture, aortic and arterial dissection, and organ injury. Some children can develop major hematomas with minimal trauma, whereas others go through childhood without a major bruise or injury. Regular physical activity contributes positively to emotional and physical health. Decisions regarding physical activity should be made using shared decision-making among the child, family, and health care professional, taking into account the child's personal risk profile.



## Surgical and Transcatheter Interventions

Surgical and catheter-based interventions carry high risk because of tissue fragility and poor healing. However, multiple cohort studies have demonstrated successful surgical intervention when specific precautions are taken, such as minimizing tissue and vascular trauma, avoiding manual angiography when possible, ensuring strict blood pressure control and tolerance of hypotension, and using soft, maneuverable guidewires and catheters.<sup>109</sup> Common complications include access site issues, iatrogenic arterial dissection, and pseudoaneurysm. See Aortic Dissection and Prophylactic Aortic Surgery and Table 5.

## Highlights: Vascular Ehlers-Danlos Syndrome

- Clinical presentation is highly variable in children. A pathogenic or likely pathogenic variant in *COL3A1* is necessary for diagnosis.
- TTE should be performed at the time of diagnosis to evaluate for congenital heart disease and assess the aortic dimensions.
- Cross-sectional imaging from head to pelvis should be performed but may be delayed until after age 3 years to avoid risks of sedation.
- Normal TTE or MRA or CTA results do not rule out the risk of an arterial event.
- Serial imaging is driven by associated risk factors (Table 1) and baseline findings.
- It is reasonable to treat children with VEDS with a 3rd-generation BB or ARB, but further study is warranted.
- Risks and benefits of any surgical or catheter-based intervention must be weighed carefully; when undertaken, precautions to minimize tissue and arterial damage should be taken, and complications should be anticipated.

## CLASSIC EHLERS-DANLOS SYNDROME

Classic EDS, formerly type I or gravis type, is one of 13 subtypes of EDS with shared features of skin hyperextensibility, generalized joint hypermobility, and tissue fragility.<sup>110</sup> Classic EDS is autosomal dominant and caused by variants in *COL5A1* or *COL5A2*, leading to abnormalities in type V collagen. Genetic testing confirms the diagnosis and rules out other conditions.

Cardiovascular findings are uncommon. The incidence of aortic dilation and valvar abnormalities (eg, BAV) is similar to that of the general population.<sup>111</sup> Mitral and tricuspid valve prolapse and regurgitation, when present, are typically mild.<sup>112</sup> Aortic dissection is exceedingly rare and not reported in children.<sup>113</sup> Intracranial aneurysms, arteriovenous fistulae, and spontaneous rupture of large arteries are rare.<sup>112</sup>

Skin findings include soft and doughy texture, easy bruising, hyperextensibility and fragility (traumatic splitting), atrophic scarring, molluscoid pseudotumors, subcutaneous spheroids, and hernias.

A baseline TTE should be performed as part of the initial diagnostic evaluation. Long-term serial aortic imaging is not necessary if initial TTE results are normal.

## ACTA2 VARIANTS

Heterozygous pathogenic variants in *ACTA2* are responsible for 10% to 14% of nonsyndromic HTAD cases.<sup>114,115</sup> In addition to thoracic aortic disease, specific *ACTA2* variants predispose individuals to PDA, occlusive vascular diseases in muscular arteries, including early-onset coronary artery disease, strokes attributable to occlusive vascular lesions resembling Moyamoya disease (MMD), and pulmonary hypertension.<sup>114,116,117</sup> Other systemic features include iris flocculi and livedo reticularis. Recurrent *ACTA2* variants disrupting arginine 149 and arginine 118 are associated with an increased risk of early-onset coronary artery disease in patients with minimal or no cardiovascular risk factors. In contrast, variations disrupting arginine 258 (R258) or arginine 179 (R179) are associated with early-onset strokes attributable to MMD-like cerebrovascular disease, PDA, or pulmonary hypertension. MMD-like cerebrovascular disease is characterized by bilateral stenosis or occlusion of the supraglenoid internal carotid arteries without collateral artery formation, straightening of the cerebrovascular arteries, fusiform aneurysms of the carotid artery proximal to the occlusive lesion, and periventricular hyperintensities suggestive of small vessel disease.

The most robust genotype–phenotype correlation involves the most severe *ACTA2* variant—a recurrent, de novo variant involving arginine 179 (R179) causing smooth muscle dysfunction syndrome.<sup>117</sup> This variant is fully penetrant <20 years of age for PDA and thoracic aortic disease, and is often associated with MMD-like cerebrovascular changes and pulmonary hypertension. Additional phenotypic features include abnormal lung development, fixed, dilated pupils (congenital mydriasis), malrotation or hypoperistalsis of the gut, and hypotonic bladder. Specific management recommendations have been published.<sup>83,118</sup>

## History and Physical Examination

Most individuals with *ACTA2* pathogenic variants who have an aortic event present with acute aortic dissections (88%); of those with type available, 63% present with Type A and 25% present with Type B dissection.<sup>119</sup> Type A dissection is usually preceded by dilation of the aortic root or ascending aorta, but not

always.<sup>120</sup> Type B dissections occur at a much younger age than Type A dissections with *ACTA2* variants (27 years versus 36 years), and aortic events are more common in men than women.<sup>119</sup> Aortic aneurysm and dissection risk has the earliest onset for *ACTA2* variants disrupting R258 and R179, with the majority of patients with smooth muscle dysfunction syndrome undergoing surgical intervention or presenting with dissection <20 years of age.<sup>83</sup> Pregnancy introduces high risk for aortic dissection.<sup>121</sup>

## Imaging

TTE should be performed at the time of diagnosis to assess the aortic root and ascending aortic dimensions; serial imaging is based on aortic size (Table 2). Patients with *ACTA2* pathogenic R179 or R258 variants and patients with PDA or MMD should be informed of the risk and symptoms of ischemic strokes or transient ischemic attacks, and should seek medical attention and undergo head imaging if symptoms occur.

## Medical Therapy

There are no data on the efficacy of prophylactic therapy for *ACTA2* or other nonsyndromic forms of HTAD. Initiation of BBs or ARBs to reduce hemodynamic stress should be considered in patients with aortic dilation or hypertension (Table 3). Medical therapy should be considered in the absence of dilation of the thoracic aorta starting in the early teen years to minimize the risk of Type B dissection. Patients with *ACTA2* R179 often have hypotension and steno-occlusive cerebrovascular disease; lower doses should be used initially, with close monitoring of blood pressure and symptoms. Although there are no data to support the routine use of antiplatelet agents and statins, antiplatelet agents could be considered in patients with MMD-like cerebrovascular occlusions, and statins could be considered late in childhood for children with *ACTA2* pathogenic variants that also predispose to atherosclerosis.

## Exercise

See Exercise and Activity and Table 4.

## Surgical Intervention

Surgical repair of a thoracic aortic aneurysm is recommended when the diameter of any segment of the aortic root or ascending aorta is  $\geq 4.5$  cm<sup>3</sup> (Table 5).<sup>3</sup> Surgical repair at a diameter  $\geq 4.2$  cm is reasonable in patients with high-risk features (Table 1).<sup>3</sup> Concurrent arch repair at the time of root or ascending aortic repair should be considered in smooth muscle dysfunction syndrome.

## OTHER HTAD GENES, INCLUDING *MYH11*, *MYLK*, *LOX*, AND *PRKG1*

### History and Physical Examination

Heterozygous pathogenic *MYH11* variants cause thoracic aneurysms involving the aortic root and ascending aorta.<sup>122</sup> Although *MYH11* variants are identified throughout the gene, only a subset of these variants in a limited region of the gene are pathogenic or likely pathogenic. Although aortic events have only been described in adults, pediatric PDA and cerebrovascular disease have been described.<sup>123,124</sup> *MYH11* carriers have fusiform dilation of the root and ascending aorta, and repair is recommended at 4.5 cm.

Heterozygous pathogenic *MYLK* variants cause thoracic aortic aneurysm and dissection in adults, with aortic dissection occurring at a relatively small dimension.<sup>77,125,126</sup> Although familial pathogenic variants have been detected in children, aortic dilation and dissection are rare in childhood.

Heterozygous pathogenic *LOX* variants also cause HTAD.<sup>10,127</sup> Individuals with *LOX* variants may have systemic manifestations similar to MFS (eg, skeletal features, joint hypermobility, dural ectasia, striae), but these features are typically insufficient to reach a clinical diagnosis of MFS. Individuals with *LOX* variants can present with aortic root dilation in childhood or later, fusiform dilation of the root and ascending aorta that can extend into the aortic arch, and Type A dissection. Aortic dimension at the time of aneurysm repair ranged from 4.2 to 10.5 cm, but data on aortic size at the time of Type A dissection are limited. Infrarenal aortic, hepatic, and brain aneurysms have been reported in members of one family, and an unrelated individual was reported with multiple aneurysms (in the infrarenal aorta, iliac, and femoral arteries).<sup>128</sup>

A single, recurrent heterozygous pathogenic *PRKG1* variant (c.530G>A, p.R177Q) is a rare cause of HTAD presenting with early-onset aortic aneurysm and dissection, as early as adolescence, with minimal or no dilation.<sup>5,77</sup> BBs should be initiated in the early teenage years, and aggressive surgical repair of the aorta should be considered regardless of the presence or absence of enlargement of the aorta.

### Imaging

A TTE should be performed at the time of diagnosis to assess the diameter of the aortic root and ascending aorta; serial imaging is based on aortic dimensions (Table 2).

### Medical Therapy

There are no data on the efficacy of prophylactic therapy for HTAD associated with *MYH11*, *MYLK*, *LOX*, or

*PRKG1* variants. Initiation of BBs or ARBs to reduce hemodynamic stress could be considered in patients with aortic dilation or hypertension, particularly if there is a family history of dissection (Table 3).

### Exercise and Surgical Intervention

See Exercise and Activity, Aortic Dissection and Prophylactic Aortic Surgery, and Tables 4 and 5.

## FLNA-RELATED CARDIOVASCULAR DISEASE

### History and Physical Examination

Heterozygous, loss-of-function sequence variations in *FLNA* are associated with X-linked periventricular nodular heterotopias and seizures<sup>129</sup> and various cardiovascular abnormalities, including dilation of the ascending aorta and aortic root (with the ascending almost always larger than the root), BAV, aortic regurgitation, PDA, valvular dysplasia, and pulmonary hypertension.<sup>6,130,131</sup> The majority of affected patients are female; hemizygosity for null variants typically leads to fetal death in male embryos.<sup>132</sup> Noncardiovascular manifestations, including obstructive lung disease, joint hypermobility, and thin, soft skin, are common.<sup>132</sup>

Thoracic aortic aneurysms associated with *FLNA* variants tend to progress. Aortic dissection and rupture are rare, but have been reported at aortic dimensions as small as 4 to 4.5 cm.<sup>131</sup> Other vascular events include myocardial ischemia, stroke, transient ischemic attack, or subarachnoid hemorrhage, at ages as young as 19 years.<sup>131</sup> The most common cause of death in infancy is lung disease with pulmonary hypertension.<sup>130</sup>

### Imaging

TTE should be performed at the time of diagnosis to identify any congenital heart disease and to assess the diameter of the aortic root and ascending aorta (Table 2). Serial imaging should be performed in all patients with *FLNA* variants, including ones with normal thoracic aortic dimensions; frequency of serial imaging depends on aortic size and rate of growth.

### Medical Therapy

There are no data on the efficacy of prophylactic therapy for *FLNA* variants. Use of BBs or ARBs to reduce hemodynamic stress have been described and should be considered in patients with aortic dilation or hypertension (see Medical Therapy and Table 3).<sup>130,131</sup> Standard medical management for pulmonary hypertension including sildenafil is reasonable.

### Exercise and Surgical Intervention

See Exercise and Activity, Aortic Dissection and Prophylactic Aortic Surgery, and Tables 4 and 5.

## ARTERIAL TORTUOSITY SYNDROME

### History and Physical Examination

Arterial tortuosity syndrome is a rare autosomal recessive condition caused by biallelic variants in *SLC2A10*. Arterial tortuosity syndrome is characterized by generalized tortuosity of large and medium-sized arteries, focal stenoses of the pulmonary arteries and aorta, aortic root and ascending aortic dilation, arterial stenoses including coarctation of the aorta, and ischemic stroke.<sup>133,134</sup> Stenoses and dilation can progress. Large aneurysms can develop, but dissection and rupture have not been reported. Dilation and tortuosity of veins are common.<sup>135</sup>

Manifestations of a generalized connective tissue disorder are common, including soft, doughy, hyperextensible skin, inguinal and diaphragmatic hernias, joint hypermobility, contractures, arachnodactyly, pectus excavatum or carinatum, and scoliosis. The face can be long, with a long philtrum and a high-arched palate. Keratoconus has been reported.<sup>133</sup>

Cardiac care is driven by lesions present in the individual.<sup>133,134</sup> Multidisciplinary care should include ophthalmology, orthopedics, and orthodontics, and monitoring for keratoconus, refractive errors, scoliosis, and dental crowding.

### Imaging

TTE should be performed at the time of diagnosis (Table 2). Comprehensive MRA or CTA (head to pelvis) is helpful to delineate the extent of tortuosity, dilation, and stenosis. Serial imaging will depend on individual findings and rate of progression.

### Medical Therapy and Surgical Intervention

There are no data on the efficacy of prophylactic therapy for arterial tortuosity syndrome. Aortic dissection and rupture have not been reported (see Medical Therapy and Table 3). ARBs should be used with caution in the presence of aortic or renal artery stenosis compromising renal blood flow.

Surgical intervention for aortic aneurysm is uncommon, although it has been performed.<sup>134,136</sup>

Pulmonary artery stenoses tend to be bilateral and multifocal in nature. Complications include right ventricular hypertension, right heart failure, exercise intolerance, and respiratory insufficiency. Other arterial stenoses are also common in arterial tortuosity

syndrome. Complications can include refractory systemic hypertension, heart failure, progressive prestenotic or poststenotic dilation, tissue ischemia, transient ischemic attack, or stroke. Intervention is individualized on the basis of vascular anatomy; both catheter-based and surgical approaches for arterial stenoses have been described.<sup>137–139</sup>

## Exercise

See Exercise and Activity and Table 4.

## AUTOSOMAL RECESSIVE CUTIS LAXA TYPE 1B (*EFEMP2*)

Autosomal recessive cutis laxa type 1B is an ultrarare condition caused by variants in *EFEMP2* (previously *FBLN4*) and characterized by cutis laxa, diffuse arterial disease (eg, extensive arterial tortuosity, aneurysms, stenoses), retrognathia, joint laxity, hernias, and arachnodactyly.<sup>7</sup> Perinatal lethality is common, often secondary to respiratory failure because of tracheobronchial compression by aneurysms.<sup>140</sup> Manifestations are highly variable. Imaging recommendations are listed in Table 2 and Supplemental Table 7. Medical therapy, interventions, and exercise guidance should be tailored to specific lesions. Arterial and aortic dissection in humans have not been described, although the mouse model is susceptible to dissection and rupture, and humans are thought to be susceptible as well.

## BICUSPID AORTIC VALVE

Bicuspid aortopathy encompasses abnormal aortic valve morphologies in association with proximal aortic dilation. BAV is the most common congenital heart disease, occurring in 0.5% to 2% of the general population, with a near 3:1 male predominance.<sup>3,71,141–143</sup> Dilation of the aortic root (20%; Z score >2) and ascending aorta (50%; Z score >2 SD) is frequent. Dilation is more commonly present with partial or total fusion of the right–left commissures, with persistent progression through childhood and adolescence.<sup>144–147</sup> Aortic dissection in children with isolated BAV without a known specific HTAD sequence variation has not been reported; however, adults with BAV and aortic aneurysm are at risk for aortic dissection.<sup>148</sup>

## History and Physical Examination

A focused aortopathy family history screens for familial aortic dilation, congenital heart disease, surgical intervention, dissection, and sudden death.<sup>148,149</sup> Physical examination includes evaluation for valvar stenosis and regurgitation, and an aortic ejection click. Genetics

evaluation is often considered in the presence of syndromic features or prominent family history of aortopathy (Figure 2).<sup>3</sup>

## Imaging

TTE offers appropriate evaluation of aortic valve morphology and function, identifies accompanying congenital heart disease, and provides accurate assessment of aortic size in most patients (Table 3).<sup>3</sup> Computed tomography or MRI may be used if TTE does not offer accurate acoustic windows.<sup>3,71</sup> Lifelong imaging surveillance is routine.<sup>3</sup> Serial TTE frequency is based on aortopathy degree, dilation rate, and valve function. First-degree relatives of individuals with BAV can have BAV, aortic dilation with trileaflet aortic valve, or both BAV and aortic dilation.<sup>150,151</sup> TTE screening for first-degree relatives is suggested and cost effective.<sup>3,71,148,152</sup>

## Medical Therapy

Medical therapy aims to decrease the rate of aortic dilation throughout childhood, but has not been studied prospectively in children with BAV. Some guidance for medical therapy has been extrapolated from more common aortopathy syndromes, and includes BBs.<sup>71</sup> A large degree of regional practice variation exists.<sup>1,69,153</sup> One retrospective study demonstrated a slower rate of aortic growth after treatment with either losartan or atenolol compared with baseline with no treatment.<sup>56</sup> A regional bicuspid aortopathy registry has agreed upon irbesartan as first-line treatment.<sup>69</sup> Table 3 summarizes a potential medication strategy, with consideration of treatment for aortic Z score >4.

## Exercise

See Exercise and Activity and Table 4.

## Surgical Intervention

Isolated bicuspid aortopathy remains an uncommon surgical indication during childhood or adolescence. Multidisciplinary surgical review is encouraged to evaluate absolute aortic dimensions and rate of dilation, accompanying aortic valve disease, and family history.<sup>3</sup> Surgical intervention is recommended for aortic dimension  $\geq 5.5$  cm, and considered between 5.0 and 5.5 cm in the presence of additional risk factors (eg, rapid growth >3 mm/year, predominant aortic root dilation, known as root phenotype, coarctation, family history of dissection) or when performed by experienced surgeons at multidisciplinary aortic centers. Surgery at aortic dimension as low as 4.5 cm can be considered for aortic valve repair or replacement at multidisciplinary aortic centers.<sup>3,71</sup>



## AORTIC DILATION ATTRIBUTABLE TO OTHER CAUSES OR WITHOUT CLEAR GENETIC CAUSE

The differential diagnosis of aortopathy in a child with a structurally normal heart and negative aortopathy testing results (Supplemental Table 10) includes presumed HTAD with negative testing; acquired pathogenesises, such as chronic hypertension or stimulant abuse; congenital complete heart block; PHACE syndrome; autoimmune or infectious aortitis; renal disease; and genetic conditions, including 22q11.2 deletion, Alagille, Noonan, or Turner syndromes and neurofibromatosis.

### Suspected HTAD With Negative Genetic Testing

Many children and adults undergoing genetic testing will not have a pathogenic variant identified on initial analysis despite clinical evidence of a genetic condition (eg, a positive family history).<sup>3</sup> Absence of a positive genetic test result should not be assumed to rule out HTAD if clinical suspicion is otherwise high. Reclassification of uncertain variants, discovery of new genes, and addition of these genes to aortopathy panels occur on an ongoing basis. Thus, continued follow-up with genetics should be considered.

### Imaging in Suspected HTAD With Negative Genetic Testing

TTE should be performed at the time of diagnosis to assess the size of the aortic root and ascending aorta; the need for serial imaging is based on aortic dimensions, age, and family history (Table 2). For patients with suspected HTAD, multiple studies have confirmed the use of screening first-degree relatives with TTE, even in the absence of positive genetic test results.<sup>3</sup> In the case of a child with aortic dilation, TTE of the parents is important, because the risk of aortic complications is greater with older age. If a parent is found to have aortic dilation, all their first-degree family members should undergo imaging. On the contrary, if a child is being evaluated because of having a gene-negative parent with aortic aneurysm, and imaging results are normal, repeat imaging should be performed in 5 to 10 years. If there is a family history of vascular disease involving the distal aorta or peripheral vasculature, cross-sectional imaging may be considered.

### Medical Therapy

There are no data on the efficacy of prophylactic therapy for the child with suspected HTAD and negative genetic testing results (see Medical Therapy and

Table 3). Clinicians should work closely with families in a shared decision-making process to weigh potential risks and benefits of medical therapy. Initiation of BBs, ARBs, or angiotensin-converting enzyme inhibitors should be considered in patients with hypertension or aggressive family history.<sup>32</sup> Calcium channel blockers are often the mainstay of therapy for patients with renal disorders.<sup>154</sup>

### Exercise and Surgical Intervention

See Exercise and Activity, Aortic Dissection and Prophylactic Aortic Surgery, and Tables 4 and 5.

## SUMMARY

Care of children with aortopathy is driven by genetic diagnosis, cardiac phenotype, family history, and age. Many advancements have been made in terms of risk stratification by condition, and stratification tools should be used to individualize and optimize care. Consultation with a pediatric aortopathy specialist should be considered, especially in complex or severe cases, or when escalation in medical therapy or surgical intervention is being considered. Smooth transition of care to a multidisciplinary adult aortopathy service is essential.

## ARTICLE INFORMATION

The American Heart Association makes every effort to avoid any actual or potential conflicts of interest that may arise as a result of an outside relationship or a personal, professional, or business interest of a member of the writing panel. Specifically, all members of the writing group are required to complete and submit a Disclosure Questionnaire showing all such relationships that might be perceived as real or potential conflicts of interest.

This statement was approved by the American Heart Association Science Advisory and Coordinating Committee on April 29, 2024, and the American Heart Association Executive Committee on June 12, 2024. A copy of the document is available at <https://professional.heart.org/statements> by using either "Search for Guidelines & Statements" or the "Browse by Topic" area. To purchase additional reprints, call 215-356-2721 or email [Meredith.Edelman@wolterskluwer.com](mailto:Meredith.Edelman@wolterskluwer.com)

The American Heart Association requests that this document be cited as follows: Morris SA, Flyer JN, Yetman AT, Quezada E, Cappella ES, Dietz HC, Milewicz DM, Ouzounian M, Rigelsky CM, Tierney S, Lacro RV, on behalf of the American Heart Association Council on Cardiovascular and Stroke Nursing; Council on Peripheral Vascular Disease; Council on Cardiopulmonary, Critical Care, Perioperative and Resuscitation; and Council on Cardiovascular Surgery and Anesthesia. Cardiovascular management of aortopathy in children: a scientific statement from the American Heart Association. *Circulation*. 2024;150:e228–e254. doi: 10.1161/CIR.0000000000001265

The expert peer review of AHA-commissioned documents (eg, scientific statements, clinical practice guidelines, systematic reviews) is conducted by the AHA Office of Science Operations. For more on AHA statements and guidelines development, visit <https://professional.heart.org/statements>. Select the "Guidelines & Statements" drop-down menu, then click "Publication Development."

Permissions: Multiple copies, modification, alteration, enhancement, and distribution of this document are not permitted without the express permission of the American Heart Association. Instructions for obtaining permission are located at <https://www.heart.org/permissions>. A link to the "Copyright Permissions Request Form" appears in the second paragraph (<https://www.heart.org/en/about-us/statements-and-policies/copyright-request-form>).

Disclosures

Writing Group Disclosures

Writing group member	Employment	Research grant	Other research support	Speakers' bureau/ honoraria	Expert witness	Ownership interest	Consultant/ advisory board	Other
Ronald V. Lacro	Boston Children's Hospital	None	None	None	None	None	None	None
Shaine A. Morris	Baylor College of Medicine, Texas Children's Hospital	Southern Star Medical Research Institute (2 grants for Marfan syndrome research)†; Centers for Disease Control†	None	None	None	None	None	None
Elizabeth S. Cappella	Lurie Children's Hospital	None	None	None	None	None	None	None
Harry C. Dietz	Johns Hopkins University Institute of Genetic Medicine	None	None	None	None	None	Aytu†	None
Jonathan N. Flyer	University of Vermont College of Medicine	None	None	None	None	None	None	None
Dianna M. Milewicz	The University of Texas Health Science Center at Houston	NIH (research on the genes predisposing to thoracic aortic disease)†; AHA (research on the cerebrovascular disease associated with ACTA2 pathogenic variants)†; Genetic Aortic Disease Association of Canada (Clinical research to define the phenotype associated with each HTAD gene)†; John Ritter Foundation (funding to recruit thoracic aortic disease patients for genetic research)†; Leducq Foundation (funding to identify the cellular and molecular basis of acute aortic dissections)†	None	None	None	None	None	None
Maral Ouzounian	Toronto General Hospital, Canada	None	None	Edwards*; Artivion*	None	None	None	None
Emilio Quezada	University of California, San Francisco	None	None	None	None	None	None	None
Christina M. Rigelsky	Cleveland Clinic Center for Personalized Genetic Healthcare	None	None	None	None	None	None	None
Seda Tierney	Stanford University	None	None	None	None	None	None	None
Anji T. Yetman	Children's Hospital & Medical Center	None	None	None	None	None	None	None

This table represents the relationships of writing group members that may be perceived as actual or reasonably perceived conflicts of interest as reported on the Disclosure Questionnaire, which all members of the writing group are required to complete and submit. A relationship is considered to be "significant" if (a) the person receives \$5000 or more during any 12-month period, or 5% or more of the person's gross income; or (b) the person owns 5% or more of the voting stock or share of the entity, or owns \$5000 or more of the fair market value of the entity. A relationship is considered to be "modest" if it is less than "significant" under the preceding definition.

†Significant.

Reviewer Disclosures

Reviewer	Employment	Research grant	Other research support	Speakers' bureau/ honoraria	Expert witness	Ownership interest	Consultant/advisory board	Other
Alan C. Braverman	Washington University School of Medicine	None	None	None	None	None	Member, Event Adjudication Committee for the ACER Clinical Trial of Celiprolol in Vascular Ehlers-Danlos Syndrome*; Member, Professional Advisory Board and Board of Directors, The Marfan Foundation*	None
Joseph A. Camarda	Ann & Robert H. Lurie Children's Hospital	None	None	None	None	None	None	None
Kathryn W. Holmes	Oregon Health & Science University	None	None	None	None	None	None	None
Denver Sallee	Children's Healthcare of Atlanta Cardiology	None	None	None	None	None	None	None
Luciana Young	Seattle Children's Hospital/University of Washington	None	None	None	None	None	None	None

This table represents the relationships of reviewers that may be perceived as actual or reasonably perceived conflicts of interest as reported on the Disclosure Questionnaire, which all reviewers are required to complete and submit. A relationship is considered to be "significant" if (a) the person receives \$5000 or more during any 12-month period, or 5% or more of the person's gross income; or (b) the person owns 5% or more of the voting stock or share of the entity, or owns \$5000 or more of the fair market value of the entity. A relationship is considered to be "modest" if it is less than "significant" under the preceding definition.

\*Modest.

## REFERENCES

- Weyland CN, Saliccioli KB, Beecroft T, Soludczyk EN, Morris SA. Evaluating variation in the cardiac management of children with hereditary thoracic aortic disease in the United States. *Pediatr Cardiol*. 2023;45:133–142. doi: 10.1007/s00246-023-03305-8
- Hiratzka LF, Bakris GL, Beckman JA, Bersin RM, Carr VF, Casey DE Jr, Eagle KA, Hermann LK, Isselbacher EM, Kazerooni EA, et al; American College of Cardiology Foundation/American Heart Association Task Force on Practice Guidelines. 2010 ACCF/AHA/AATS/ACR/ASA/SCA/SCAI/SIR/STS/SVM guidelines for the diagnosis and management of patients with thoracic aortic disease: a report of the American College of Cardiology Foundation/American Heart Association Task Force on Practice Guidelines, American Association for Thoracic Surgery, American College of Radiology, American Stroke Association, Society of Cardiovascular Anesthesiologists, Society for Cardiovascular Angiography and Interventions, Society of Interventional Radiology, Society of Thoracic Surgeons, and Society for Vascular Medicine. *Circulation*. 2010;121:e266–e369. doi: 10.1161/CIR.0b013e3181d4739e
- Isselbacher EM, Preventza O, Black JH 3rd, Augoustides JG, Beck AW, Bolen MA, Braverman AC, Bray BE, Brown-Zimmerman MM, Chen EP, et al. 2022 ACC/AHA guideline for the diagnosis and management of aortic disease: a report of the American Heart Association/American College of Cardiology joint committee on clinical practice guidelines. *Circulation*. 2022;146:e334–e482. doi: 10.1161/CIR.0000000000001106
- Silberbach M, Roos-Hesselink JW, Andersen NH, Braverman AC, Brown N, Collins RT, De Backer J, Eagle KA, Hiratzka LF, Johnson WH Jr, et al; American Heart Association Council on Cardiovascular Disease in the Young; Council on Genomic and Precision Medicine; and Council on Peripheral Vascular Disease. Cardiovascular health in Turner syndrome: a scientific statement from the American Heart Association. *Circ Genom Precis Med*. 2018;11:e000048. doi: 10.1161/HCG.0000000000000048
- Milewicz DM, Cecchi AC. Heritable thoracic aortic disease overview. Updated May 4, 2023. In: Adam MP, Feldman J, Mirzaa GM, et al, eds. *GeneReviews [Internet]*. University of Washington. <https://www.ncbi.nlm.nih.gov/books/NBK1120>
- Meester JAN, Vandeweyer G, Pintelon I, Lammens M, Hoorick LV, Belder SD, Waitzman K, Young L, Markham LW, Vogt J, et al. Loss-of-function mutations in the X-linked biglycan gene cause a severe syndromic form of thoracic aortic aneurysms and dissections. *Genet Med*. 2017;19:386–395. doi: 10.1038/gim.2016.126
- Loeys B, De Paepe A, Urban Z. *EFEMP2*-related cutis laxa. Updated June 15, 2023. In: Adam MP, Feldman J, Mirzaa GM, et al, eds. *GeneReviews [Internet]*. University of Washington. <https://www.ncbi.nlm.nih.gov/books/NBK54467>
- Kuang S-Q, Medina-Martinez O, Guo D, Gong L, Regalado ES, Reynolds CL, Boileau C, Jondeau G, Prakash SK, Kwartler CS, et al. *FOXO3* mutations predispose to thoracic aortic aneurysms and dissections. *J Clin Invest*. 2016;126:948–961. doi: 10.1172/JCI83778
- Greally MT. Shprintzen-Goldberg syndrome. Updated April 9, 2020. In: Adam MP, Feldman J, Mirzaa GM, et al, eds. *GeneReviews [Internet]*. University of Washington. <https://www.ncbi.nlm.nih.gov/books/NBK1277>
- Guo D, Regalado ES, Gong L, Duan X, Santos-Cortez RLP, Arnaud P, Ren Z, Cai B, Hostettler EM, Moran R, et al; University of Washington Center for Mendelian Genomics. *LOX* mutations predispose to thoracic aortic aneurysms and dissections. *Circ Res*. 2016;118:928–934. doi: 10.1161/CIRCRESAHA.115.307130
- Ponińska JK, Pelczar-Płachta W, Pollak A, Jończyk-Potoczna K, Truszkowska G, Michałowska I, Szafran E, Bilińska ZT, Bobkowski W, Płoski R. Double heterozygous pathogenic variants in the *LOX* and *PKD1* genes in a 5-year-old patient with thoracic aortic aneurysm and polycystic kidney disease. *Genes*. 2023;14:1983. doi: 10.3390/genes14111983
- Gucht IV, Krebsova A, Diness BR, Laga S, Adlam D, Kempers M, Samani NJ, Webb TR, Baranowska AA, Heuvel LVD, et al. Novel *LOX* variants in five families with aortic/arterial aneurysm and dissection with variable connective tissue findings. *Int J Mol Sci*. 2021;22:7111. doi: 10.3390/ijms22137111
- Gouda P, Kay R, Habib M, Aziz A, Aziza E, Welsh R. Clinical features and complications of Loeys-Dietz syndrome: a systematic review. *Int J Cardiol*. 2022;362:158–167. doi: 10.1016/j.ijcard.2022.05.065
- Carley ME, Schaffer J. Urinary incontinence and pelvic organ prolapse in women with Marfan or Ehlers-Danlos syndrome. *Am J Obstet Gynecol*. 2000;182:1021–1023. doi: 10.1067/mob.2000.105410
- Pepin MG, Schwarze U, Rice KM, Liu M, Leistritz D, Byers PH. Survival is affected by mutation type and molecular mechanism in vascular Ehlers-Danlos syndrome (EDS type IV). *Genet Med*. 2014;16:881–888. doi: 10.1038/gim.2014.72
- Roman MJ, Devereux RB, Preiss LR, Asch FM, Eagle KA, Holmes KW, LeMaire SA, Maslen CL, Milewicz DM, Morris SA, et al. Associations of age and sex with Marfan phenotype. *Circ Cardiovasc Genet*. 2018;10:e001647. doi: 10.1161/CIRCGENETICS.116.001647
- Franken R, den Hartog AW, van de Riet L, Timmermans J, Scholte AJ, van den Berg MP, de Waard V, Zwiderman AH, Groenink M, Yip JW, et al. Clinical features differ substantially between Caucasian and Asian populations of Marfan syndrome. *Circ J*. 2013;77:2793–2798. doi: 10.1253/circj.13-0584
- Villamizar C, Regalado ES, Fadulu VT, Hasham SN, Gupta P, Willing MC, Kuang S-Q, Guo D, Muilenburg A, Yee RW, et al. Paucity of skeletal manifestations in Hispanic families with *FBN1* mutations. *Eur J Med Genet*. 2010;53:80–84. doi: 10.1016/j.jmg.2009.11.001
- Albornoz G, Coady MA, Roberts M, Davies RR, Tranquilli M, Rizzo JA, Elefteriades JA. Familial thoracic aortic aneurysms and dissections: incidence, modes of inheritance, and phenotypic patterns. *Ann Thorac Surg*. 2006;82:1400–1405. doi: 10.1016/j.athoracsur.2006.04.098
- Lai WW, Geva T, Shirali GS, Frommelt PC, Humes RA, Brook MM, Pignatelli RH, Rychik J; Task Force of the Pediatric Council of the American Society of Echocardiography. Guidelines and standards for performance of a pediatric echocardiogram: a report from the task force of the Pediatric Council of the American Society of Echocardiography. *J Am Soc Echocardiogr*. 2006;19:1413–1430. doi: 10.1016/j.echo.2006.09.001
- Lopez L, Colan SD, Frommelt PC, Ensing GJ, Kendall K, Younoszai AK, Lai WW, Geva T. Recommendations for quantification methods during the performance of a pediatric echocardiogram: a report from the pediatric measurements writing group of the American Society of Echocardiography Pediatric and Congenital Heart Disease Council. *J Am Soc Echocardiogr*. 2010;23:465–495; quiz 576. doi: 10.1016/j.echo.2010.03.019
- Colan SD. The why and how of Z scores. *J Am Soc Echocardiogr*. 2013;26:38–40. doi: 10.1016/j.echo.2012.11.005
- Boston Children's Hospital Heart Center. Boston Z-score calculator. <https://zscore.chboston.org>
- Lopez L, Frommelt PC, Colan SD, Trachtenberg FL, Gongwer R, Stylianou M, Bhat A, Burns KM, Cohen MS, Dragulescu A, et al; Pediatric Heart Network Investigators. Pediatric Heart Network echocardiographic Z scores: comparison with other published models. *J Am Soc Echocardiogr*. 2021;34:185–192. doi: 10.1016/j.echo.2020.09.019
- Braley KT, Tang X, Makil ES, Borroughs-Ray D, Collins RT. The impact of body weight on the diagnosis of aortic dilation: misdiagnosis in overweight and underweight groups. *Echocardiography*. 2017;34:1029–1034. doi: 10.1111/echo.13565
- Nejatian A, Yu J, Geva T, White MT, Prakash A. Aortic measurements in patients with aortopathy are larger and more reproducible by cardiac magnetic resonance compared with echocardiography. *Pediatr Cardiol*. 2015;36:1761–1773. doi: 10.1007/s00246-015-1231-4
- Nussbaumer C, Bouchardy J, Blanche C, Piccini D, Pavon A-G, Monney P, Stuber M, Schwitler J, Rutz T. 2D cine vs. 3D self-navigated free-breathing high-resolution whole heart cardiovascular magnetic resonance for aortic root measurements in congenital heart disease. *J Cardiovasc Magn Reson*. 2021;23:65. doi: 10.1186/s12968-021-00744-1
- McCann ME, Soriano SG. Does general anesthesia affect neurodevelopment in infants and children? *BMJ*. 2019;367:l6459. doi: 10.1136/bmj.l6459
- Morris SA, Orbach DB, Geva T, Singh MN, Gauvreau K, Lacro RV. Increased vertebral artery tortuosity index is associated with adverse outcomes in children and young adults with connective tissue disorders. *Circulation*. 2011;124:388–396. doi: 10.1161/CIRCULATIONAHA.110.990549
- Franken R, el Morabit A, de Waard V, Timmermans J, Scholte AJ, van den Berg MP, Marquering H, Planken NRN, Zwiderman AH, Mulder BJM, et al. Increased aortic tortuosity indicates a more severe aortic phenotype in adults with Marfan syndrome. *Int J Cardiol*. 2015;194:7–12. doi: 10.1016/j.ijcard.2015.05.072
- Stephens SB, Shalhub S, Dodd N, Li J, Huang M, Oda S, Kancherla K, Doan TT, Prakash SK, Weigand JD, et al. Vertebral tortuosity is associated with increased rate of cardiovascular events in vascular Ehlers-Danlos syndrome. *J Am Heart Assoc*. 2023;12:e029518. doi: 10.1161/JAHA.123.029518
- Veiga-Fernández A, Prieto LJ, Álvarez T, Ruiz Y, Pérez R, Gámez F, Abad VO, Yllana F, León-Luis JD. Perinatal diagnosis and management of early-onset Marfan syndrome: case report and systematic review. *J Matern Fetal Neonatal Med*. 2020;33:2493–2504. doi: 10.1080/14767058.2018.1552935
- Russo ML, Gandhi M, Al-Koutly HB, Morris SA. Prenatal ultrasound features of Loeys-Dietz syndrome type 4. *Ultrasound Obstet Gynecol*. 2021;57:504–506. doi: 10.1002/uog.22003

34. Byers PH. Vascular Ehlers-Danlos syndrome. Updated February 21, 2019. In: Adam MP, Feldman J, Mirzaa GM, et al, eds. *GeneReviews [Internet]*. University of Washington. <https://www.ncbi.nlm.nih.gov/books/NBK1494>
35. Caruana M, Baars MJ, Bashardes E, Benke K, Björck E, Codreanu A, de Moya Rubio E, Dumfarth J, Evangelista A, Groenink M, et al. HTAD patient pathway: strategy for diagnostic work-up of patients and families with (suspected) heritable thoracic aortic diseases (HTAD): a statement from the HTAD working group of VASCERN. *Eur J Med Genet*. 2023;66:104673. doi: 10.1016/j.jmg.2022.104673
36. Renner S, Schüller H, Alawi M, Kolbe V, Rybczynski M, Woitschach R, Sheikhzadeh S, Stark VC, Olfe J, Roser E, et al. Next-generation sequencing of 32 genes associated with hereditary aortopathies and related disorders of connective tissue in a cohort of 199 patients. *Genet Med*. 2019;21:1832–1841. doi: 10.1038/s41436-019-0435-z
37. Hicks KL, Byers PH, Quiroga E, Pepin MG, Shalhoub S. Testing patterns for genetically triggered aortic and arterial aneurysms and dissections at an academic center. *J Vasc Surg*. 2018;68:701–711. doi: 10.1016/j.jvs.2017.12.023
38. Overwater E, Marsili L, Baars MJH, Baas AF, van de Beek I, Duffer E, Hagen JM, Hiihorst-Hofstee Y, Kempers M, Krapels IP, et al. Results of next-generation sequencing gene panel diagnostics including copy-number variation analysis in 810 patients suspected of heritable thoracic aortic disorders. *Hum Mutat*. 2018;39:1173–1192. doi: 10.1002/humu.23565
39. Proost D, Vandeweyer G, Meester JAN, Salemink S, Kempers M, Ingram C, Peeters N, Saenen J, Vrints C, Lacro RV, et al. Performant mutation identification using targeted next-generation sequencing of 14 thoracic aortic aneurysm genes. *Hum Mutat*. 2015;36:808–814. doi: 10.1002/humu.22802
40. Wooderchak-Donahue W, VanSant-Webb C, Tvrdik T, Plant P, Lewis T, Stocks J, Raney JA, Meyers L, Berg A, Rope AF, et al. Clinical utility of a next generation sequencing panel assay for Marfan and Marfan-like syndromes featuring aortopathy. *Am J Med Genet A*. 2015;167:1747–1757. doi: 10.1002/ajmg.a.37085
41. Backer JD, Bondue A, Budts W, Evangelista A, Gallego P, Jondeau G, Loeys B, Peña ML, Teixido-Tura G, van de Laar I, et al. Genetic counselling and testing in adults with congenital heart disease: a consensus document of the ESC Working Group of Grown-Up Congenital Heart Disease, the ESC Working Group on Aorta and Peripheral Vascular Disease and the European Society of Human Genetics. *Eur J Prev Cardiol*. 2019;27:1423–1435. doi: 10.1177/2047487319854552
42. Ahmad F, McNally EM, Ackerman MJ, Baty LC, Day SM, Kullo IJ, Madueme PC, Maron MS, Martinez MW, Salberg L, et al; on behalf of the American Heart Association Council on Genomic and Precision Medicine; Council on Arteriosclerosis, Thrombosis and Vascular Biology; Council on Basic Cardiovascular Sciences; Council on Cardiovascular and Stroke Nursing; Council on Clinical Cardiology; and Stroke Council. Establishment of specialized clinical cardiovascular genetics programs: recognizing the need and meeting standards: a scientific statement from the American Heart Association. *Circ Genom Precis Med*. 2019;12:e000054. doi: 10.1161/HCG.0000000000000054
43. Richards S, Aziz N, Bale S, Bick D, Das S, Gastier-Foster J, Grody WW, Hegde M, Lyon E, Spector E, et al; ACMG Laboratory Quality Assurance Committee. Standards and guidelines for the interpretation of sequence variants: a joint consensus recommendation of the American College of Medical Genetics and Genomics and the Association for Molecular Pathology. *Genet Med*. 2015;17:405–424. doi: 10.1038/gim.2015.30
44. Landstrom AP, Chahal AA, Ackerman MJ, Cresci S, Milewicz DM, Morris AA, Sarquella-Brugada G, Semsarian C, Shah SH, Sturm AC; on behalf of the American Heart Association Data Science and Precision Medicine Committee of the Council on Genomic and Precision Medicine and Council on Clinical Cardiology; Council on Cardiovascular and Stroke Nursing; Council on Hypertension; Council on Lifelong Congenital Heart Disease and Heart Health in the Young; Council on Peripheral Vascular Disease; and Stroke Council. Interpreting incidentally identified variants in genes associated with heritable cardiovascular disease: a scientific statement from the American Heart Association. *Circ Genom Precis Med*. 2023;16:e000092. doi: 10.1161/HCG.0000000000000092
45. Baudhuin LM, Kluge ML, Kotzer KE, Lagerstedt SA. Variability in gene-based knowledge impacts variant classification: an analysis of FBN1 missense variants in ClinVar. *Eur J Hum Genet*. 2019;27:1550–1560. doi: 10.1038/s41431-019-0440-3
46. Shores J, Berger KR, Murphy EA, Pyeritz RE. Progression of aortic dilatation and the benefit of long-term  $\beta$ -adrenergic blockade in Marfan's syndrome. *N Engl J Med*. 1994;330:1335–1341. doi: 10.1056/nejm199405123301902
47. Groenink M, den Hartog AW, Franken R, Radonic T, de Waard V, Timmermans J, Scholte AJ, van den Berg MP, Spijkerboer AM, Marquering HA, et al. Losartan reduces aortic dilatation rate in adults with Marfan syndrome: a randomized controlled trial. *Eur Heart J*. 2013;34:3491–3500. doi: 10.1093/eurheartj/ehs334
48. Lacro RV, Dietz HC, Sleeper LA, Yetman AT, Bradley TJ, Colan SD, Pearson GD, Tierney ESS, Levine JC, Atz AM, et al; Pediatric Heart Network Investigators. Atenolol versus losartan in children and young adults with Marfan's syndrome. *N Engl J Med*. 2014;371:2061–2071. doi: 10.1056/NEJMoa1404731
49. Milleron O, Arnoult F, Ropers J, Aegerter P, Detaint D, Delorme G, Attias D, Tubach F, Dupuis-Girod S, Plauchu H, et al. Marfan Sartan: a randomized, double-blind, placebo-controlled trial. *Eur Heart J*. 2015;36:2160–2166. doi: 10.1093/eurheartj/ehv151
50. Sander GGS, Alghamdi MH, Raffin LA, Potts MT, Williams LD, Potts JE, Kiess M, van Breemen C. A randomized, double blind pilot study to assess the effects of losartan vs. atenolol on the biophysical properties of the aorta in patients with Marfan and Loeys-Dietz syndromes. *Int J Cardiol*. 2015;179:470–475. doi: 10.1016/j.ijcard.2014.11.082
51. Forteza A, Evangelista A, Sánchez V, Teixido-Tura G, Sanz P, Gutiérrez L, Gracia T, Centeno J, Rodríguez-Palomares J, Rufilanchas JJ, et al. Efficacy of losartan vs. atenolol for the prevention of aortic dilation in Marfan syndrome: a randomized clinical trial. *Eur Heart J*. 2016;37:978–985. doi: 10.1093/eurheartj/ehv575
52. Muñoz-Mosquera L, De Nobele S, Devos D, Campens L, De Paepe A, Backer JD. Efficacy of losartan as add-on therapy to prevent aortic growth and ventricular dysfunction in patients with Marfan syndrome: a randomized, double-blind clinical trial. *Acta Cardiol*. 2017;72:1–9. doi: 10.1080/00015385.2017.1314134
53. Mullen M, Jin XY, Child A, Stuart AG, Dodd M, Aragon-Martin JA, Gaze D, Kiotseoglou A, Yuan L, Hu J, et al. Irbesartan in Marfan syndrome (AIMS): a double-blind, placebo-controlled randomised trial. *Lancet*. 2020;394:2263–2270. doi: 10.1016/S0140-6736(19)32518-8
54. Pitcher A, Spata E, Emberson J, Davies K, Halls H, Holland L, Wilson K, Reith C, Child AH, Clayton T, et al. Angiotensin receptor blockers and  $\beta$  blockers in Marfan syndrome: an individual patient data meta-analysis of randomised trials. *Lancet*. 2022;400:822–831. doi: 10.1016/S0140-6736(22)01534-3
55. Ong K-T, Perdu J, Backer JD, Bozec E, Collignon P, Emmerich J, Faure A-L, Fiessinger J-N, Germain DP, Georgesco G, et al. Effect of celirolol on prevention of cardiovascular events in vascular Ehlers-Danlos syndrome: a prospective randomised, open, blinded-endpoints trial. *Lancet*. 2010;376:1476–1484. doi: 10.1016/S0140-6736(10)60960-9
56. Flyer JN, Sleeper LA, Colan SD, Singh MN, Lacro RV. Effect of losartan or atenolol on children and young adults with bicuspid aortic valve and dilated aorta. *Am J Cardiol*. 2021;144:111–117. doi: 10.1016/j.amjcard.2020.12.050
57. US Food and Drug Administration. FDA warns about increased risk of ruptures or tears in the aorta blood vessel with fluoroquinolone antibiotics in certain patients. Published May 10, 2017. <https://www.fda.gov/drugs/drug-safety-and-availability/fda-warns-about-increased-risk-ruptures-or-tears-aorta-blood-vessel-fluoroquinolone-antibiotics>
58. Chen S-W, Chan Y-H, Wu VC-C, Cheng Y-T, Chen D-Y, Lin C-P, Hung K-C, Chang S-H, Chu P-H, Chou A-H. Effects of fluoroquinolones on outcomes of patients with aortic dissection or aneurysm. *J Am Coll Cardiol*. 2021;77:1875–1887. doi: 10.1016/j.jacc.2021.02.047
59. Chen S-W, Lin C-P, Chan Y-H, Wu VC-C, Cheng Y-T, Tung Y-C, Hsiao F-C, Chen D-Y, Hung K-C, Chou A-H, et al. Fluoroquinolones and risk of aortic aneurysm or dissection in patients with congenital aortic disease and Marfan syndrome. *Circ J*. 2023;87:1164–1172. doi: 10.1253/circj.CJ-22-0682
60. Brown JP, Wing K, Leyrat C, Evans SJ, Mansfield KE, Wong AYS, Smeeth L, Galwey NW, Douglas IJ. Association between fluoroquinolone use and hospitalization with aortic aneurysm or aortic dissection. *JAMA Cardiol*. 2023;8:865–870. doi: 10.1001/jamacardio.2023.2418
61. Alwan S, Polifka JE, Friedman JM. Angiotensin II receptor antagonist treatment during pregnancy. *Birth Defects Res A Clin Mol Teratol*. 2005;73:123–130. doi: 10.1002/bdra.20102
62. Hofman KJ, Bernhardt BA, Pyeritz RE, Opitz JM, Reynolds JF. Marfan syndrome: neuropsychological aspects. *Am J Med Genet*. 1988;31:331–338. doi: 10.1002/ajmg.1320310210
63. Coghill D, Banaschewski T, Cortese S, Asherson P, Brandeis D, Buitelaar J, Daley D, Danckaerts M, Dittmann RW, Doepfner M, et al. The management of ADHD in children and adolescents: bringing evidence to the clinic: perspective from the European ADHD Guidelines Group (EAGG). *Eur Child Adolesc Psychiatry*. 2023;32:1337–1361. doi: 10.1007/s00787-021-01871-x
64. Storebø OJ, Storm MRO, Ribeiro JP, Skoog M, Groth C, Callesen HE, Schaug JP, Rasmussen PD, Huus C-ML, Zwi M, et al. Methylphenidate



for children and adolescents with attention deficit hyperactivity disorder (ADHD). *Cochrane Database Syst Rev*. 2023;2023:CD009885. doi: 10.1002/14651858.CD009885.pub3

65. Doyle JJ, Doyle AJ, Wilson NK, Habashi JP, Bedja D, Whitworth RE, Lindsay ME, Schoenhoff F, Myers L, Huso N, et al. A deleterious gene-by-environment interaction imposed by calcium channel blockers in Marfan syndrome. *Life*. 2015;4:e08648. doi: 10.7554/eLife.08648
66. Maron BJ, Chaitman BR, Ackerman MJ, de Luna AB, Corrado D, Crosson JE, Deal BJ, Driscoll DJ, Estes NAM 3rd, Araújo CGS, et al; for the Working Groups of the American Heart Association Committee on Exercise, Cardiac Rehabilitation, and Prevention; Councils on Clinical Cardiology and Cardiovascular Disease in the Young. Recommendations for physical activity and recreational sports participation for young patients with genetic cardiovascular diseases. *Circulation*. 2004;109:2807–2816. doi: 10.1161/01.CIR.0000128363.85581.E1
67. Braverman AC, Harris KM, Kovacs RJ, Maron BJ; on behalf of the American Heart Association Electrocardiography and Arrhythmias Committee of the Council on Clinical Cardiology, Council on Cardiovascular Disease in the Young, Council on Cardiovascular and Stroke Nursing, Council on Functional Genomics and Translational Biology, and American College of Cardiology. Eligibility and disqualification recommendations for competitive athletes with cardiovascular abnormalities: task force 7: aortic diseases, including Marfan syndrome: a scientific statement from the American Heart Association and American College of Cardiology. *Circulation*. 2015;132:e303–e309. doi: 10.1161/CIR.0000000000000243
68. Baleilevuka-Hart M, Teng BJ, Carson KA, Ravekes WJ, Holmes KW. Sports participation and exercise restriction in children with isolated bicuspid aortic valve. *Am J Cardiol*. 2020;125:1673–1677. doi: 10.1016/j.amjcard.2020.02.039
69. Flyer JN, Goudie BW, Greenstein EP, Toro-Salazar OH, Nikolli K, Sleeper LA, Clarke CJ, Hidestrand P, Karnik R, O'Brien SE, et al. New England Congenital Cardiology Association Bicuspid Aortopathy Registry (NECCA BAR): a regional preventive cardiovascular care collaboration. *Prog Pediatr Cardiol*. 2022;66:101543. doi: 10.1016/j.ppedcard.2022.101543
70. Hebson C, Iannucci G. Bicuspid aortopathy and sports clearance. *Am J Cardiol*. 2021;147:147–148. doi: 10.1016/j.amjcard.2021.02.008
71. Erbel R, Aboyans V, Boileau C, Bossone E, Bartolomeo RD, Eggebrecht H, Evangelista A, Falk V, Frank H, Gaemperli O, et al. 2014 ESC guidelines on the diagnosis and treatment of aortic diseases: document covering acute and chronic aortic diseases of the thoracic and abdominal aorta of the adult: The Task Force for the Diagnosis and Treatment of Aortic Diseases of the European Society of Cardiology (ESC). *Eur Heart J*. 2014;35:2873–2926. doi: 10.1093/eurheartj/ehu281
72. Hatzaras I, Tranquilli M, Coady M, Barrett PM, Bible J, Elefteriades JA. Weight lifting and aortic dissection: more evidence for a connection. *Cardiology*. 2007;107:103–106. doi: 10.1159/000094530
73. Monda E, Verrillo F, Rubino M, Palmiero G, Fusco A, Cirillo A, Caiazza M, Guarnaccia N, Mauriello A, Lioncino M, et al. Thoracic aortic dilation: implications for physical activity and sport participation. *Diagnostics (Basel)*. 2022;12:1392. doi: 10.3390/diagnostics12061392
74. Bonow RO, Cheitlin MD, Crawford MH, Douglas PS. Task force 3: valvular heart disease. *J Am Coll Cardiol*. 2005;45:1334–1340. doi: 10.1016/j.jacc.2005.02.010
75. Tierney ESS, Chung S, Stauffer KJ, Brabender J, Collins II RT, Folk R, Li W, Murthy AK, Murphy DJ, Esfandiari M. Can 10 000 healthy steps a day slow aortic root dilation in pediatric patients with Marfan syndrome? *J Am Heart Assoc*. 2022;11:e027598. doi: 10.1161/JAHA.122.027598
76. Delsart P, Maldonado-Kauffmann P, Bic M, Boudghene-Stambouli F, Sobocinski J, Juthier F, Domanski O, Coisne A, Azaoui R, Rousse N, et al. Post aortic dissection: gap between activity recommendation and real life patients aerobic capacities. *Int J Cardiol*. 2016;219:271–276. doi: 10.1016/j.ijcard.2016.06.026
77. Regalado ES, Morris SA, Braverman AC, Hostettler EM, Backer JD, Li R, Pyeritz RE, Yetman AT, Cervi E, Shalhub S, et al. Comparative risks of initial aortic events associated with genetic thoracic aortic disease. *J Am Coll Cardiol*. 2022;80:857–869. doi: 10.1016/j.jacc.2022.05.054
78. Jondeau G, Ropers J, Regalado E, Braverman A, Evangelista A, Teixedo G, Backer JD, Muñoz-Mosquera L, Naudion S, Zordan C, et al. International registry of patients carrying TGFBR1 or TGFBR2 mutations. *Circ Cardiovasc Genet*. 2016;9:548–558. doi: 10.1161/CIRCGENETICS.116.001485
79. Gott VL, Greene PS, Alejo DE, Cameron DE, Naftel DC, Miller DC, Gillinov AM, Laschinger JC, Borst HG, Cabrol CEA, et al. Replacement of the aortic root in patients with Marfan's syndrome. *N Engl J Med*. 1999;340:1307–1313. doi: 10.1056/NEJM199904293401702
80. Pressler V, McNamara JJ. Aneurysm of the thoracic aorta: review of 260 cases. *J Thorac Cardiovasc Surg*. 1985;89:50–54.
81. Malaisrie SC, Duncan BF, Mehta CK, Badiwala MV, Rinewalt D, Kruse J, Li Z, Andrei A-C, McCarthy PM. The addition of hemiarch replacement to aortic root surgery does not affect safety. *J Thorac Cardiovasc Surg*. 2015;150:118–124. doi: 10.1016/j.jtcvs.2015.03.020
82. Preventza O, Coselli JS, Price MD, Simpson KH, Yafei O, de la Cruz KI, Zhang Q, Green S. Elective primary aortic root replacement with and without hemiarch repair in patients with no previous cardiac surgery. *J Thorac Cardiovasc Surg*. 2017;153:1402–1408. doi: 10.1016/j.jtcvs.2016.10.076
83. Regalado ES, Mellor-Crummey L, Backer JD, Braverman AC, Ades L, Benedict S, Bradley TJ, Brickner ME, Chatfield KC, Child A, et al. Clinical history and management recommendations of the smooth muscle dysfunction syndrome due to ACTA2 arginine 179 alterations. *Genet Med*. 2016;20:1206–1215. doi: 10.1038/gim.2017.245
84. Fraser CD, Liu RH, Zhou X, Patel ND, Lui C, Pierre AS, Jacobs ML, Dietz HC, Habashi J, Hibino N, et al. Valve-sparing aortic root replacement in children: outcomes from 100 consecutive cases. *J Thorac Cardiovasc Surg*. 2018;157:1100–1109. doi: 10.1016/j.jtcvs.2018.09.148
85. Patel ND, Alejo D, Crawford T, Hibino N, Dietz HC, Cameron DE, Vricella LA. Aortic root replacement for children with Loeys-Dietz syndrome. *Ann Thorac Surg*. 2017;103:1513–1518. doi: 10.1016/j.athoracsurg.2017.01.053
86. Everitt MD, Pinto N, Hawkins JA, Mitchell MB, Kouretas PC, Yetman AT. Cardiovascular surgery in children with Marfan syndrome or Loeys-Dietz syndrome. *J Thorac Cardiovasc Surg*. 2009;137:1327–1332. doi: 10.1016/j.jtcvs.2009.02.007
87. Knadler JJ, LeMaire S, McKenzie ED, Moffett B, Morris SA. Thoracic aortic, aortic valve and mitral valve surgery in pediatric and young adult patients with Marfan syndrome: characteristics and outcomes. *Seminars Thorac Cardiovasc Surg*. 2019;31:818–825. doi: 10.1053/j.semtcvs.2019.06.005
88. Hoof LV, Rega F, Goleworthy T, Verbrugge P, Austin C, Takkenberg JMM, Pepper JR, Treasure T. Personalised external aortic root support for elective treatment of aortic root dilation in 200 patients. *Heart*. 2021;107:1790–1795. doi: 10.1136/heartjnl-2021-319300
89. Milewicz DM, Braverman AC, Backer JD, Morris SA, Boileau C, Maumenee IH, Jondeau G, Evangelista A, Pyeritz RE, Backer JD. Marfan syndrome. *Nat Rev Dis Primers*. 2021;7:64. doi: 10.1038/s41572-021-00298-7
90. Pyeritz RE. Marfan syndrome: improved clinical history results in expanded natural history. *Genet Med*. 2019;21:1683–1690. doi: 10.1038/s41436-018-0399-4
91. Demolder A, Timmermans F, Duytschaever M, Muñoz-Mosquera L, Backer JD. Association of mitral annular disjunction with cardiovascular outcomes among patients with Marfan syndrome. *JAMA Cardiol*. 2021;6:1177–1186. doi: 10.1001/jamacardio.2021.2312
92. Zarate YA, Morris SA, Blackshare A, Algaze CA, Connor BS, Kim AJ, Yutzy KE, Miller EM, Weaver KN, Collins RT. A clinical scoring system for early onset (neonatal) Marfan syndrome. *Genet Med*. 2022;24:1503–1511. doi: 10.1016/j.jgm.2022.03.016
93. Loeys BL, Dietz HC, Braverman AC, Callewaert BL, Backer JD, Devereux RB, Hilhorst-Hofstee Y, Jondeau G, Faivre L, Milewicz DM, et al. The revised Ghent nosology for the Marfan syndrome. *J Med Genet*. 2010;47:476. doi: 10.1136/jmg.2009.072785
94. Loeys BL, Dietz HC. Loeys-Dietz syndrome. Updated March 1, 2018. In: Adam MP, Feldman J, Mirzaa GM, et al, eds. *GeneReviews [Internet]*. University of Washington. <https://www.ncbi.nlm.nih.gov/books/NBK1133>
95. Schepers D, Tortora G, Morisaki H, MacCarrick G, Lindsay M, Liang D, Mehta SG, Hague J, Verhagen J, de Laar I, et al. A mutation update on the LDS-associated genes TGFBR2/3 and SMAD2/3. *Hum Mutat*. 2018;39:621–634. doi: 10.1002/humu.23407
96. Liu RH, Fraser CD, Zhou X, Cameron DE, Vricella LA, Hibino N. Pseudoaneurysm formation after valve sparing root replacement in children with Loeys-Dietz syndrome. *J Card Surg*. 2018;33:339–343. doi: 10.1111/jocs.13709
97. Park I, Yang J-H, Sung K, Jun T-G, Kang I-S, Huh J, Song JY, Park PW. Valve-sparing root replacement in children with connective tissue disease: long-term risk of aortic events [published online October 27, 2023]. *J Thorac Cardiovasc Surg*. doi: 10.1016/j.jtcvs.2023.10.041. [https://www.jtcvs.org/article/S0022-5223\(23\)00998-4/abstract](https://www.jtcvs.org/article/S0022-5223(23)00998-4/abstract)
98. Schoenhoff FS, Alejo DE, Black JH, Crawford TC, Dietz HC, Grimm JC, Magruder JT, Patel ND, Vricella LA, Young A, et al. Management of the aortic arch in patients with Loeys-Dietz syndrome. *J Thorac Cardiovasc Surg*. 2020;160:1166–1175. doi: 10.1016/j.jtcvs.2019.07.130
99. Pepin M, Schwarze U, Superti-Furga A, Byers PH. Clinical and genetic features of Ehlers-Danlos syndrome type IV, the vascular type. *N Engl J Med*. 2000;342:673–680. doi: 10.1056/nejm200003093421001

100. Kaadan MI, MacDonald C, Ponzini F, Duran J, Newell K, Pitler L, Lin A, Weinberg I, Wood MJ, Lindsay ME. Prospective cardiovascular genetics evaluation in spontaneous coronary artery dissection. *Circ Genom Precis Med*. 2018;11:e001933. doi: 10.1161/CIRCGENETICS.117.001933
101. Shalhub S, Byers PH, Hicks KL, Charlton-Ouw K, Zarkowsky D, Coleman DM, Davis FM, Regalado ES, Caridi GD, Weaver KN, et al. A multi-institutional experience in the aortic and arterial pathology in individuals with genetically confirmed vascular Ehlers-Danlos syndrome. *J Vasc Surg*. 2019;70:1543–1554. doi: 10.1016/j.jvs.2019.01.069
102. Frank M, Adham S, Seigle S, Legrand A, Mirault T, Hennequin P, Albuissou J, Denarié N, Mazzella J-M, Mousseau E, et al. Vascular Ehlers-Danlos syndrome long-term observational study. *J Am Coll Cardiol*. 2019;73:1948–1957. doi: 10.1016/j.jacc.2019.01.058
103. van de Laar IMBH, Baas AF, De Backer J, Blankenstein JD, Duffer E, Helderma-van den Enden ATJM, Houweling AC, Kempers MJE, Loeys B, Malfait F, et al. Surveillance and monitoring in vascular Ehlers-Danlos syndrome in European Reference Network For Rare Vascular Diseases (VASCERN). *Eur J Med Genet*. 2022;65:104557. doi: 10.1016/j.ejmg.2022.104557
104. Bowen JM, Hernandez M, Johnson DS, Green C, Kammin T, Baker D, Keigwin S, Makino S, Taylor N, Watson O, et al. Diagnosis and management of vascular Ehlers-Danlos syndrome: experience of the UK national diagnostic service, Sheffield. *Eur J Hum Genet*. 2023;31:749–760. doi: 10.1038/s41431-023-01343-7
105. Shalhub S, Byers PH. Endovascular repair of a common iliac artery aneurysm with an iliac branch device in a patient with vascular Ehlers-Danlos syndrome due to a null COL3A1 variant. *J Vasc Surg Cases Innov Tech*. 2023;9:101192. doi: 10.1016/j.jvscit.2023.101192
106. Kalia R, Kalia R, Cubelo M, Musih J, Popat J. Clinically suspected exercise-induced myocarditis in a patient with vascular Ehlers-Danlos syndrome. *Cureus*. 2022;14:e29689. doi: 10.7759/cureus.29689
107. Levine MP. Survival of an aortic trauma patient with Ehlers-Danlos syndrome type IV: a case report. *J Vasc Surg*. 2000;32:1219–1221. doi: 10.1067/mva.2000.107993
108. Johansen H, Velvin G, Lidal I. Adults with Loeys-Dietz syndrome and vascular Ehlers-Danlos syndrome: a cross-sectional study of patient experiences with physical activity. *Disabil Rehabil*. 2022;44:1968–1975. doi: 10.1080/09638288.2020.1815874
109. Padmanaban V, Yee PP, Koduri S, Zaidat B, Daou BJ, Chaudhary N, Gemmette JJ, Thompson BG, Kazmierczak CD, Cockroft KM, et al. Neuroendovascular procedures in patients with Ehlers-Danlos type IV: multicenter case series and systematic review. *World Neurosurg*. 2023;170:e529–e541. doi: 10.1016/j.wneu.2022.11.067
110. Malfait F, Francomano C, Byers P, Belmont J, Berglund B, Black J, Bloom L, Bowen JM, Brady AF, Burrows NP, et al. The 2017 international classification of the Ehlers-Danlos syndromes. *Am J Med Genet C Semin Med Genet*. 2017;175:8–26. doi: 10.1002/ajmg.c.31552
111. Paige SL, Lechich KM, Tierney ESS, Collins RT. Cardiac involvement in classical or hypermobile Ehlers-Danlos syndrome is uncommon. *Genet Med*. 2020;22:1583–1588. doi: 10.1038/s41436-020-0856-8
112. Malfait F, Symoens S, Syx D. Classic Ehlers-Danlos syndrome. Updated February 1, 2024. In: Adam MP, Feldman J, Mirzaa GM, et al, eds. *GeneReviews [Internet]*. University of Washington. Accessed February 14, 2024. <https://www.ncbi.nlm.nih.gov/books/NBK1244>
113. Caley L, Campar A, Mendonça T, Farinha F. Aortic dissection in a patient with novel frameshift COL5A1 variant of classical Ehlers-Danlos syndrome. *Eur J Case Rep Intern Med*. 2022;10:003698. doi: 10.12890/2023\_003698
114. Guo D-C, Papke CL, Tran-Fadulu V, Regalado ES, Avidan N, Johnson RJ, Kim DH, Pannu H, Willing MC, Sparks E, et al. Mutations in smooth muscle alpha-actin (ACTA2) cause coronary artery disease, stroke, and Moyamoya disease, along with thoracic aortic disease. *Am J Hum Genet*. 2009;84:617–627. doi: 10.1016/j.ajhg.2009.04.007
115. Morisaki H, Akutsu K, Ogino H, Kondo N, Yamanaka I, Tsutsumi Y, Yoshimuta T, Okajima T, Matsuda H, Minatoya K, et al. Mutation of ACTA2 gene as an important cause of familial and nonfamilial nonsyndromic thoracic aortic aneurysm and/or dissection (TAAD). *Hum Mutat*. 2009;30:1406–1411. doi: 10.1002/humu.21081
116. Guo D-C, Pannu H, Tran-Fadulu V, Papke CL, Yu RK, Avidan N, Bourgeois S, Estrera AL, Safi HJ, Sparks E, et al. Mutations in smooth muscle  $\alpha$ -actin (ACTA2) lead to thoracic aortic aneurysms and dissections. *Nat Genet*. 2007;39:1488–1493. doi: 10.1038/ng.2007.6
117. Milewicz DM, Østergaard JR, Ala-Kokko LM, Khan N, Grange DK, Mendoza-Londono R, Bradley TJ, Olney AH, Adès L, Maher JF, et al. De novo ACTA2 mutation causes a novel syndrome of multisystemic smooth muscle dysfunction. *Am J Med Genet A*. 2010;152A:2437–2443. doi: 10.1002/ajmg.a.33657
118. Lauer A, Speroni SL, Patel JB, Regalado E, Choi M, Smith E, Kalpathy-Kramer J, Caruso P, Milewicz DM, Musolino PL. Cerebrovascular disease progression in patients with ACTA2 Arg179 pathogenic variants. *Neurology*. 2020;96:e538–e552. doi: 10.1212/WNL.00000000000011210
119. Regalado ES, Guo D, Prakash S, Benseid TA, Flynn K, Estrera A, Safi H, Liang D, Hyland J, Child A, et al. Aortic disease presentation and outcome associated with ACTA2 mutations. *Circ Cardiovasc Genet*. 2015;8:457–464. doi: 10.1161/CIRCGENETICS.114.000943
120. van den Bersselaar LM, Verhagen JMA, Bekkers JA, Kempers M, Houweling AC, Baars M, Overwater E, Hilhorst-Hofstee Y, Barge-Schaapveld DQCM, Rompen E, et al. Expanding the genetic and phenotypic spectrum of ACTA2-related vasculopathies in a Dutch cohort. *Genet Med*. 2022;24:2112–2122. doi: 10.1016/j.gim.2022.07.009
121. Regalado ES, Guo D, Estrera AL, Buja LM, Milewicz DM. Acute aortic dissections with pregnancy in women with ACTA2 mutations. *Am J Med Genet Part A*. 2014;164:106–112. doi: 10.1002/ajmg.a.36208
122. Zhu L, Vranckx R, Kien PKV, Lalande A, Boisset N, Mathieu F, Wegman M, Glancy L, Gasc J-M, Brunotte F, et al. Mutations in myosin heavy chain 11 cause a syndrome associating thoracic aortic aneurysm/aortic dissection and patent ductus arteriosus. *Nat Genet*. 2006;38:343–349. doi: 10.1038/ng1721
123. Chesneau B, Plancke A, Rolland G, Marcheix B, Dulac Y, Edouard T, Plaisancié J, Aubert-Mucca M, Julia S, Langeois M, et al. A +3 variant at a donor splice site leads to a skipping of the MYH11 exon 32, a recurrent RNA defect causing heritable thoracic aortic aneurysm and dissection and/or patent ductus arteriosus. *Mol Genet Genom Med*. 2021;9:e1814. doi: 10.1002/mggg.3.1814
124. Keylock A, Hong Y, Saunders D, Omoyinmi E, Mulhern C, Roebuck D, Brogan P, Ganesan V, Eleftheriou D. Moyamoya-like cerebrovascular disease in a child with a novel mutation in myosin heavy chain 11. *Neurology*. 2017;90:136–138. doi: 10.1212/WNL.0000000000004828
125. Luyckx I, Proost D, Hendriks JMH, Saenen J, Craenenbroeck EMV, Vermeulen T, Peeters N, Wuyts W, Rodrigus I, Verstraeten A, et al. Two novel MYLK nonsense mutations causing thoracic aortic aneurysms/dissections in patients without apparent family history. *Clin Genet*. 2017;92:444–446. doi: 10.1111/cge.13000
126. Wallace SE, Regalado ES, Gong L, Janda AL, Guo D, Russo CF, Kulmacz RJ, Hanna N, Jondeau G, Boileau C, et al. MYLK pathogenic variants aortic disease presentation, pregnancy risk, and characterization of pathogenic missense variants. *Genet Med*. 2019;21:144–151. doi: 10.1038/s41436-018-0038-0
127. Lee VS, Halabi CM, Hoffman EP, Carmichael N, Leshchiner I, Lian CG, Bierhals AJ, Vuzman D, Brigham Genomic Medicine, Mecham RP, et al. Loss of function mutation in LOX causes thoracic aortic aneurysm and dissection in humans. *Proc Natl Acad Sci*. 2016;113:8759–8764. doi: 10.1073/pnas.1601442113
128. Cirnu A, Kolokotronis K, Walz K, Kiliç A, Janz A, Williams T, Busch A, Rost S, Gerull B. Novel mutation in LOX associates with a complex aneurysmal vascular and cardiac phenotype. *Circ Genom Precis Med*. 2021;14:e003217. doi: 10.1161/CIRCGEN.120.003217
129. Chen MH, Walsh CA. FLNA deficiency. Updated September 30, 2021. In: Adam M, Feldman J, Mirzaa G, et al, eds. *GeneReviews [Internet]*. University of Washington. <https://www.ncbi.nlm.nih.gov/books/NBK1213>
130. Burrage LC, Guillerman RP, Das S, Singh S, Schady DA, Morris SA, Walkiewicz M, Schecter MG, Heinle JS, Lotze TE, et al. Lung transplantation for FLNA-associated progressive lung disease. *J Pediatr*. 2017;186:118–123.e6. doi: 10.1016/j.jpeds.2017.03.045
131. Chen MH, Choudhury S, Hirata M, Khalsa S, Chang B, Walsh CA. Thoracic aortic aneurysm in patients with loss of function filamin A mutations: clinical characterization, genetics, and recommendations. *Am J Med Genet A*. 2018;176:337–350. doi: 10.1002/ajmg.a.38580
132. Reinstein E, Frentz S, Morgan T, García-Miñaur S, Leventer RJ, McGillivray G, Pariani M, van der Steen A, Pope M, Holder-Espinasse M, et al. Vascular and connective tissue anomalies associated with X-linked periventricular heterotopia due to mutations in Filamin A. *Eur J Hum Genet*. 2013;21:494–502. doi: 10.1038/ejhg.2012.209
133. Callewaert B, De Paepe A, Coucke P. Arterial tortuosity syndrome. Updated February 23, 2023. In: Adam MP, Feldman J, Mirzaa GM, et al, eds. *GeneReviews*. University of Washington. <https://pubmed.ncbi.nlm.nih.gov/25392904>

134. Beyens A, Albuissou J, Boel A, Al-Essa M, Al-Manea W, Bonnet D, Bostan O, Boute O, Busa T, Canham N, et al. Arterial tortuosity syndrome: 40 new families and literature review. *Genet Med*. 2018;20:1236–1245. doi: 10.1038/gim.2017.253
135. Mocerì P, Albuissou J, Saint-Faust M, Casagrande F, Giuliano F, Devos C, Benoit P, Hugues N, Ducreux D, Cerboni P, et al. Arterial tortuosity syndrome early diagnosis and association with venous tortuosity. *J Am Coll Cardiol*. 2013;61:783. doi: 10.1016/j.jacc.2012.06.070
136. Bottio T, Bisleri G, Piccoli P, Muneretto C. Valve-sparing aortic root replacement in a patient with a rare connective tissue disorder: arterial tortuosity syndrome. *J Thorac Cardiovasc Surg*. 2007;133:252–253. doi: 10.1016/j.jtcvs.2006.08.050
137. Cobb H, Spray B, Daily J, Dossey A, Angtuaco MJ. Cutting balloon angioplasty on branch pulmonary artery stenosis in pediatric patients. *Catheter Cardiovasc Interv*. 2021;98:526–532. doi: 10.1002/ccd.29803
138. Felmy LM, Mainwaring RD, Collins RT, Lechich K, Martin E, Ma M, Hanley FL. Surgical repair of peripheral pulmonary artery stenosis: a 2-decade experience with 145 patients. *J Thorac Cardiovasc Surg*. 2023;165:1493–1502.e2. doi: 10.1016/j.jtcvs.2022.07.037
139. Alkhalidi A, Momenah T, Alsaahri A, Alotay A, Alfonso JJ, Abuzaid A, Alwadaï A. Late outcomes after pulmonary arterial reconstruction in patients with arterial tortuosity syndrome. *Ann Thorac Surg*. 2021;113:1569–1574. doi: 10.1016/j.athoracsur.2021.03.063
140. Kappanayil M, Nampoothiri S, Kannan R, Renard M, Coucke P, Malfait F, Menon S, Ravindran HK, Kurup R, Faiyaz-Ul-Haque M, et al. Characterization of a distinct lethal arteriopathy syndrome in twenty-two infants associated with an identical, novel mutation in FBLN4 gene, confirms fibulin-4 as a critical determinant of human vascular elastogenesis. *Orphanet J Rare Dis*. 2012;7:61–61. doi: 10.1186/1750-1172-7-61
141. Roberts WC. The congenitally bicuspid aortic valve: a study of 85 autopsy cases. *Am J Cardiol*. 1970;26:72–83. doi: 10.1016/0002-9149(70)90761-7
142. Steinberger J, Moller JH, Berry JM, Sinaiko AR. Echocardiographic diagnosis of heart disease in apparently healthy adolescents. *Pediatrics*. 2000;105:815–818. doi: 10.1542/peds.105.4.815
143. Basso C, Boschello M, Perrone C, Mecenero A, Cera A, Bicego D, Thiene G, Dominici ED. An echocardiographic survey of primary school children for bicuspid aortic valve. *Am J Cardiol*. 2004;93:661–663. doi: 10.1016/j.amjcard.2003.11.031
144. Beroukhi RS, Kruzick TL, Taylor AL, Gao D, Yetman AT. Progression of aortic dilation in children with a functionally normal bicuspid aortic valve. *Am J Cardiol*. 2006;98:828–830. doi: 10.1016/j.amjcard.2006.04.022
145. Holmes KW, Lehmann CU, Dalal D, Nasir K, Dietz HC, Ravekes WJ, Thompson WR, Spevak PJ. Progressive dilation of the ascending aorta in children with isolated bicuspid aortic valve. *Am J Cardiol*. 2007;99:978–983. doi: 10.1016/j.amjcard.2006.10.065
146. Verma S, Siu SC. Aortic dilatation in patients with bicuspid aortic valve. *N Engl J Med*. 2014;370:1920–1929. doi: 10.1056/NEJMra1207059
147. Fernandes S, Khairy P, Graham DA, Colan SD, Galvin TC, Sanders SP, Singh MN, Bhatt A, Lacro RV. Bicuspid aortic valve and associated aortic dilation in the young. *Heart*. 2012;98:1014–1019. doi: 10.1136/heartjnl-2012-301773
148. Glotzbach JP, Hanson HA, Tonna JE, Horns JJ, Allen CM, Presson AP, Griffin CL, Zak M, Sharma V, Tristani-Firouzi M, et al. Familial associations of prevalence and cause-specific mortality for thoracic aortic disease and bicuspid aortic valve in a large-population database. *Circulation*. 2023;148:637–647. doi: 10.1161/CIRCULATIONAHA.122.060439
149. Bray JJH, Freer R, Pitcher A, Kharbada R. Family screening for bicuspid aortic valve and aortic dilatation: a meta-analysis. *Eur Heart J*. 2023;44:3152–3164. doi: 10.1093/eurheartj/ehad320
150. Dayan V, Zuasnabar A, Citro R, Bossone E, Michelena HI, Parma G, Bellino M, Olascoaga A, Florio L, Body S; Bicuspid Aortic Valve Consortium: BAVCON. Aortopathy and regurgitation in bicuspid valve patients increase the risk of aortopathy in relatives. *Int J Cardiol*. 2019;286:117–120. doi: 10.1016/j.ijcard.2019.03.031
151. Biner S, Rafique AM, Ray I, Cuk O, Siegel RJ, Tolstrup K. Aortopathy is prevalent in relatives of bicuspid aortic valve patients. *J Am Coll Cardiol*. 2009;53:2288–2295. doi: 10.1016/j.jacc.2009.03.027
152. Tessler I, Leshno M, Shmueli A, Shpitzen S, Durst R, Gilon D. Cost-effectiveness analysis of screening for first-degree relatives of patients with bicuspid aortic valve. *Eur Heart J Qual Care Clin Outcomes*. 2021;7:447–457. doi: 10.1093/ehjqcco/qcab047
153. Hussain A, Warren AE, Chen RPC, Dhillon SS. Practice variation among Canadian pediatric cardiologists in medical management of dilated ascending aorta in patients with bicuspid aortic valve. *CJC Open*. 2019;1:119–122. doi: 10.1016/j.cjco.2019.03.002
154. Mitsnefes MM, Wühl E. Role of hypertension in progression of pediatric CKD. *Pediatr Nephrol*. 2023;38:3519–3528. doi: 10.1007/s00467-023-05894-1